

Molecular Diagnosis of 5 α -Reductase Deficiency in 4 Elite Young Female Athletes Through Hormonal Screening for Hyperandrogenism

Patrick Fénichel, Françoise Paris, Pascal Philibert, Sylvie Hiéronimus, Laura Gaspari, Jean-Yves Kurzenne, Patrick Chevallier, Stéphane Bermon, Nicolas Chevalier, and Charles Sultan

Department of Reproductive Endocrinology and Institut National de la Santé et de la Recherche Médicale Unité 1065 (P.F., S.H., N.C.), Hospital of L'Archet, University Hospital of Nice, 06200 Nice, France; Department of Hormonology and Pediatric Endocrinology (F.P., P.P., L.G., C.S.), Lapeyronie Hospital, Centre Hospitalier Universitaire, 34295 Montpellier, France; Departments of Pediatrics (J.-Y.K.) and Medical Imaging (P.C.), Centre Hospitalier Universitaire Nice, France; and Monaco Institute for Sport Medicine and Surgery (IM2S) (S.B.), 98000 Monaco

Context: Although a rare occurrence, previously undiagnosed disorders of sex development (DSD) with hyperandrogenism are sometimes detected by hormonal screening during the international sports competitions. Identifying the cause of XY,DSD raises medical and ethical concerns, especially with regard to issues of the eligibility to compete.

Objective: The aim of this study was to determine whether the detection of high plasma T in young elite female athletes during hormonal screening would reveal an unsuspected XY DSD.

Setting: The study was performed in the Nice and Montpellier University Hospitals (France), which collaborate as reference centers for DSD in elite athletes on behalf of sports governing bodies.

Patients: Four cases of elite young athletes with female phenotypes but high plasma T detected during hormonal screening were investigated for undiagnosed XY DSD.

Main Outcome Measures: Evaluation of clinical, biological, radiological (magnetic resonance imaging and dual-energy x-ray absorptiometry) and genetic characteristics was conducted.

Results: The 4 athletes presented as tall, slim, muscular women with a male bone morphotype, no breast development, clitoromegaly, partial or complete labial fusion, and inguinal/intralabial testes. All reported primary amenorrhea. The hormonal analysis evidenced plasma T within the male range, the karyotype was 46, XY, and molecular analysis of the 5 α -reductase type 2 (*srd5A2*) gene identified a homozygotic mutation in 2 cases, a heterozygotic compound in 1 case, and a deletion in 1 case.

Conclusion: 5 α -Reductase deficiency should be investigated in elite young female athletes with primary amenorrhea and high male T levels detected during antidoping programs to identify undiagnosed XY DSD. (*J Clin Endocrinol Metab* 98: E1055–E1059, 2013)

The world of sports has struggled with the issue of gender abnormalities since the Olympic Games of Berlin in 1936 (1). The matter of systematic screening for ab-

normal virilization in female athletes remains still controversial. The major question is whether this condition provides unfair advantages. The focus is not so much on

ISSN Print 0021-972X ISSN Online 1945-7197

Printed in U.S.A.

Copyright © 2013 by The Endocrine Society

Received November 13, 2012. Accepted April 16, 2013.

First Published Online April 30, 2013

Abbreviations: CAIS, complete androgen insensitivity syndrome; DHT, dihydrotestosterone; DSD, disorder of sex differentiation; MRI, magnetic resonance imaging; SRD5A2, deficiency in 5 α -reductase type 2.

uncovering cases of masquerading or anabolic doping but on detecting those athletes who are competing unknowingly with a disorder of sex differentiation (DSD). A systematic gender verification program was first established in 1966, with clinical inspection, Barr body screening, and later sex-determining region, Y chromosome DNA detection by PCR, a decision that created controversy and caused considerable embarrassment (2). The decision to abandon compulsory gender verification in Olympic competition was made in 1999. Today the new systematic hormonal screening in phenotypically female athletes (3) may be a good opportunity to identify unknown XY DSD with primary amenorrhea and hyperandrogenism.

Partial androgen insensitivity syndrome or minimal androgen insensitivity syndrome may be implicated, but not complete androgen insensitivity syndrome (CAIS), because in patients with CAIS, plasma T is very high but inactive. Another cause of XY DSD with possible hyperandrogenic amenorrhea is a deficiency in 5 α -reductase type 2 (SRD5A2) activity. This is a very rare disorder characterized by high phenotypical variability. The spectrum actually ranges from isolated micropenis or hypospadias to severe undervirilization appearing as normal female external genitalia with mild clitoral enlargement (4). The diagnosis is made either at birth or at puberty when there is virilization on the external genitalia through either the androgen receptor binding of very high levels of serum T, albeit at lower affinity, or the increased expression of extragenital 5 α -reductase type 1, which results in low peripheral synthesis of dihydrotestosterone (DHT) from T (5).

We report for the first time the diagnosis of 5 α -reductase deficiency in 4 hyperandrogenic elite female athletes.

Patients and Methods

Four elite young amenorrheic athletes with hyperandrogenism were referred to our Reproductive Endocrinology Department. Case 1 was identified through an abnormal urine steroid profile and clitoral hypertrophy reported by the antidoping officer, whereas cases 2 and 4 through increased plasma T, and free androgen index and LH results collected as a part of the Athlete Biological Passport (3). Case 3 was directly referred to the international federation medical department by her national federation doctor.

Blood samples were taken for endocrine investigation and for karyotyping and genetic analysis after informed consent was obtained. Steroids and polypeptide hormones were assayed by radioimmunological methods currently used in the University Hospital of Nice. Abdominal-pelvic magnetic resonance imaging (MRI) was systematically performed, as was dual-energy x-ray biphotonic absorp-

tiometry (Hologic, Bedford, Massachusetts) to determine bone mineral density and corporeal composition (comparison with a female control population).

Molecular analysis of the *SRD5A2* gene was performed in the Department of Hormonology of the University Hospital of Montpellier. Genomic DNA was extracted from peripheral blood leukocytes following the manufacturer's instructions (DNA QIAamp DNA blood minikit; QIAGEN, Courtaboeuf, France). As previously reported (6), exons 1–5 of the *SRD5A2* gene were amplified by PCR, and direct sequencing was performed using the BigDye terminator version 1.1 kit (Applied Biosystems, Courtaboeuf, France) and an AB1 Prism 310 genetic analyzer (Applied Biosystems). For this retrospective clinical study, institutional review board/Independent Ethics Committee approval for publication is not required in France.

Results

The 4 young amenorrheic women, respectively, 18, 20, 21, and 20 years of age at diagnosis, were from rural or mountainous regions of developing countries. They had never menstruated and this primary amenorrhea had never been evaluated. Consanguinity was confirmed for 3 of them (first cousins in cases 2 and 3 and siblings in case 4) and was suspected in the fourth case (case 1), with the 2 parents originating from neighboring villages (Table 1). All had several brothers and sisters, including 1 sister who had been surgically treated for a DSD (nonverified; case 2) and 1 infertile (case 3) (Table 1). They all reported unexpected virilization at puberty with excessive pubic hair or clitoromegaly. In all cases, they had manifested strong motivation and high tolerance to intensive daily training, which had made them good candidates for elite sports competition. However, none of them reported male sex behavior.

The clinical characteristics were quite similar, with all presenting as tall, slim, and muscular young women but with a complete lack of breast development and android bone morphotype (high biacromial/birotrochanteric diameter ratio) (Table 1). Axillary hair growth was slight and pubic hair was female triangular, and none presented with hirsutism. Clinical inspection of the external genitalia revealed clitoromegaly in all cases, almost complete labial fusion in cases 2 and 4, partial fusion in cases 1 and 3, and a single urogenital orifice in cases 2 and 4 (types 2–4 of the Prader classification) (Table 1). Clinical palpation of the major labia or inguinal region and MRI of the abdominal-pelvic region determined the nature and size of the testes and localized them at the inguinal orifice in cases 1 and 2, intralabial in case 4, and 1 at the inguinal orifice and the other sublabial in case 2 (Table 1). MRI confirmed the lack

Table 1. Clinical and Biological Aspects

Patient	Age at Diagnosis, y	Consanguinity	Height/Weight, m/kg	Bioacromial/Bitrochanteric			Prader Class	Labial Fusion	Testis Inguinal or Labial	DEXA		
				cm	Ratio ^a					Vertebral Z Score	Femoral Z Score	Fat Mass, %
1	18	Possible	1, 78/65	41/30	1, 3	2/3	Partial	Inguinal/inguinal	-2	+0.1	8.5	
2	20	Cousins	1, 71/61	40/29	1, 37	3	Complete	Inguinal/labial	-2.4	-1.7	8.3	
3	21	Cousins	1, 63/65	43/35	1, 23	2/3	Partial	Inguinal/inguinal	-0.1	+2.5	14.0	
4	20	Siblings	1, 72/61	35/26	1, 34	3/4	Complete	Labial/labial	+1.1	-0.1	9.4	
	Total T, ng/mL [0.09–0.99]	DHT, ng/mL [0.04–0.27]	T to DHT Ratio	D4, ng/mL [0.4–2.3]	17 OHP, ng/mL [0.1–2.9]	E2, pg/mL [19–214]	LH, IU/L [1.5–70]	FSH, IU/L [4–33]	AMH, ng/mL [0.87–9.6]	Inhibin B, ng/mL [10–200]		
1	6.2	2.4	2.5	1.5	2.3	60	9.9	11.6	8.1	22		
2	6.4	0.2	31.7	2.4	1.1	<10	4.9	23	6.3	11.6		
3	5.2	0.12	43.6	1.9	2.2	24	13.9	21.8	5.5	13.8		
4	6.3	0.3	19.3	1.9	1.1	41	6.2	13.7	2.7	52		

Abbreviations: AMH, anti-Mullerian hormone; DEXA, dual-energy x-ray absorptiometry; E2, estradiol; 17OHP, 17-hydroxyprogesterone.

^a Female ratio 1, 1; male ratio 1, 3 (18).

of Mullerian ducts and the presence of intrapelvic seminal vesicles and a rudimentary prostate in all athletes, whereas a short blinded vagina (<22 mm) was identified in cases 1, 2, and 3. In addition, the vertebral bone mineral content was decreased in cases 1 and 2 compared with standards for females (Table 1).

Table 1 summarizes the hormonal features, showing a male range of basal plasma total T with elevated gonadotropins and normal male estradiol, 17-hydroxyprogesterone, anti-Mullerian hormone, and inhibin B. DHT was decreased with an increased T to DHT ratio except for case 1.

Chromosomal analysis confirmed a 46, XY karyotype. The combination of primary amenorrhea, lack of breast development, clitoromegaly, a female pubic hair pattern, and high T levels prompted the molecular analysis of the *SRD5A2* gene by direct sequencing, which revealed a homozygous mutation in 2 cases in exon 1 (p.Gly34Arg; case 1) and in exon 4 (p.Asn.193Ser; case 2), a compound heterozygous mutation in exon 4 in case 4, (p.[Arg227X]+[Ala228Thr]), and an exon 1 deletion in case 3 (Figure 1). Regarding the compound heterozygous

mutation (case 4), we confirmed by direct sequencing that 1 mutation was inherited from the father, whereas the other was inherited from the mother.

In contrast to the tendency to request gender change, our 4 athletes wished to maintain their female identity and had many questions about menstruation, sexual activity, and child-bearing. Although leaving male gonads in *SRD5A2* patients carries no health risk, each athlete was informed that gonadectomy would most likely decrease their performance level but allow them to continue elite sport in the female category. We thus proposed a partial clitoridectomy with a bilateral gonadectomy, followed by a deferred feminizing vaginoplasty and estrogen replacement therapy, to which the 4 athletes agreed after informed consent on surgical and medical procedures. Sports authorities then allowed them to continue competing in the female category 1 year after gonadectomy.

Discussion

We report here for the first time the cases of 4 elite young amenorrheic athletes who were diagnosed with *SRD5A2*

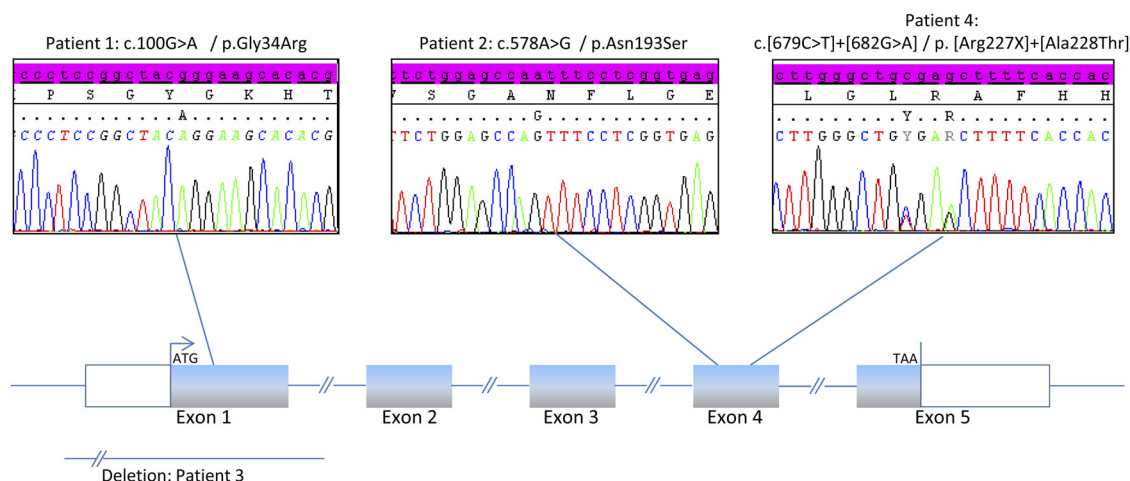


Figure 1. Sequencing electrophoregrams showing the different mutants identified in the 4 athletes with *SRD5A2* deficiency.

deficiency after high androgen levels and have been revealed during implementation of an antidoping program.

In these 4 46, XY DSD cases with female phenotype and high plasma T, the lack of breast development suggested SRD5A2 deficiency, even though DHT was not completely abolished, as reported in our previous experience (7) or by others (8). We identified 2 known homozygous missense mutations of SRD5A2 (p.Asn193Ser and p.Gly34Arg), 1 new complete exon 1 deletion, and a compound heterozygous mutation in exon 4 (p.[Arg227X]+[Ala228Thr]).

To our knowledge, the complete exon 1 deletion, identified in case 3, has never been reported. Conversely, the substitution of asparagine by serine at position 193 (p.Asn193Ser) identified in homozygous form in case 2 was reported by our group in a 16-year-old Polish girl who exhibited clitoral enlargement and virilization (6). Similarly, the p.Gly34Arg mutation found in case 1 was described in a 35-year-old Vietnamese woman with primary amenorrhea, no breast development, and clitoromegaly (8, 9). Regarding the compound heterozygous mutation p.[Arg227X]+[Ala228Thr] (case 4), the former mutation was reported in homozygous form in a 16-year-old Mexican girl with no breast development, primary amenorrhea and virilization (8) and in a 6-year-old boy with micropenis, posterior hypospadias, but no cryptorchidism (9), whereas the latter mutation was reported in homozygous form in a patient of Eritrean origin who presented at birth with perineal hypospadias, a hypoplastic scrotum with both gonads palpable in the inguinal canal, and a micropenis (10).

The delay in diagnosing these athletes may be explained by the slight degree of genital malformation generally observed in such cases at birth. Virilization then occurs at puberty due to the rise in T and the 5 α -reductase type I enzyme (11–13), with a possible female-to-male gender switch and/or a marked behavioral change (7, 13, 14). However, it is possible that the gender abnormalities of these athletes were clearly recognized at birth, especially for cases 2 and 4, but not formally diagnosed or given medical attention because they had been born in rural regions of countries with poor care.

The estimated incidence of severe 46, XY DSD with uncertain sex is 2.2 per 10 000 births (15), and SRD5A2 deficiency accounts for 6.7% of such cases (16), for a set incidence of 1 per 100 000 (0.001%). In 1996 the systematic sex-determining region, Y chromosome screening in female athletes (2) during the Atlanta Olympic Games revealed 8 46XY DSD cases of 3384 (1 of 423) including 1 case (1 of 3384) of SRD5A2 deficiency (known to but hidden by the athlete herself). More recently, during a World Championship, a massive systematic blood testing program was for the first time conducted: 868 top female

level athletes participated in this implementation of the Athlete Biological Passport (3). Two cases of hyperandrogenism led to the diagnosis of SRD5A2 deficiency for an incidence of at least 1 of 434 (some cases are still pending), which is more than 200 times the estimated incidence in the general population. These unpublished preliminary results suggest that the high active T during the fetal, postnatal, or peripubertal period in cases of SRD5A2 deficiency may confer a selective advantage for sports, likely through the brain, muscle, and/or bone morphotype.

The bone morphotype in our patients was android but, curiously, the vertebral bone mineral content was decreased in 2 patients compared with standards for females.

One of the main issues that has emerged with regard to 46, XY DSD hyperandrogenic athletes is the issue of protecting their health, private life, integrity, and rights but maintaining strict standards of fairness for all women. This has led to the guidelines proposed by the International Association of Athletics Federations (<http://www.iaaf.org/medical/policy/index.html>), accepted by the International Olympic Committee and recently commented in this journal (17). Except for cases of CAIS with inactive T, women with 46XY DSD will be allowed to compete only when T blood levels decrease on less than 10 nmol/L, the lower limit for males (17).

In this work, we demonstrate that young competitive female athletes may be affected by an SRD5A2 deficiency. It is thus important to screen for SRD5A2 deficiency in all young athletes with primary amenorrhea and hyperandrogenism to protect their health and privacy and ensure fairness in female competition.

Acknowledgments

Address all correspondence and requests for reprints to: Patrick Fénichel, MD, PhD, Researcher, Institut National de la Santé et de la Recherche Médicale and Nice University Department of Endocrinology, 06200 Nice, France. E-mail: fénichel.p@chu-nice.fr.

Disclosure Summary: The authors have nothing to declare.

References

1. Ritchie RJ, Reynard J, Lewis T. Intersex and the Olympic Games. *R Soc Med*. 2008;101:395–399.
2. Elsas LJ, Ljungqvist A, Ferguson-Smith MA, et al. Gender verification of female athletes. *Genet Med*. 2000;2:249–254.
3. Sottas PE, Vernec A. Current implementation and future of the Athlete Biological Passport. *Bioanalysis*. 2012;13:1645–1652.
4. Maimoun L, Philibert P, Cammas B, et al. Phenotypical, biological, and molecular heterogeneity of 5 α -reductase deficiency: an extensive international experience of 55 patients. *J Clin Endocrinol Metab*. 2011;96:296–307.
5. Azzouni F, Godoy A, Li Y, Mohler J. The 5 alpha-reductase isozyme

- family: a review of basic biology and their role in human diseases *Adv Urol*. 2012;2012:530121.
6. Boudon C, Lombroso S, Lobacaro JM, et al. Molecular study of the 5 α -reductase type 2 gene in three European families with 5 α -reductase deficiency. *J Clin Endocrinol Metab*. 1995;80:2149–2153.
 7. Maimoun L, Philibert P, Bouchard P, et al. Primary amenorrhea in four adolescents revealed 5 α -reductase deficiency confirmed by molecular analysis. *Fertil Steril*. 2011;95:804.e1–5.
 8. Johnson L, George FW, Neaves WB, et al. Characterization of the testicular abnormality in 5 α -reductase deficiency. *J Clin Endocrinol Metab*. 1986;63:1091–1099.
 9. Thigpen AE, Davis DL, Milatovich A, et al. Molecular genetics of steroid 5 α -reductase 2 deficiency. *J Clin Invest*. 1992;90:799–809.
 10. Hiort O, Sinnecker GH, Willenbring H, Lehnert A, Zöllner A, Struve D. Nonisotopic single strand conformation analysis of the 5 α -reductase type 2 gene for the diagnosis of 5 α -reductase deficiency. *J Clin Endocrinol Metab*. 1996;81:3415–3418.
 11. Imperato-McGinley J, Peterson RE, Gautier T, Sturla E. Androgens and the evolution of male-gender identity among male pseudohermaphrodites with 5 α -reductase deficiency. *N Engl J Med*. 1979;300:1233–1237.
 12. Thiele S, Hoppe U, Holterhus PM, Hiort O. Isoenzyme type 1 of 5 α -reductase is abundantly transcribed in normal human genital skin fibroblasts and may play an important role in masculinization of 5 α -reductase type 2 deficient males. *Eur J Endocrinol*. 2005;152:875–880.
 13. Houk CP, Dzamiani D, Lee PA. Choice of gender in 5 α reductase-2 deficiency: a moving target. *J Pediatr Endocrinol Metab*. 2005;18:339–345.
 14. Mendonca BB, Inacio M, Costa EM, Arnhold IJ, Silva FA, Nicolau W. Male pseudohermaphroditism due to steroid 5 α reductase 2 deficiency. Diagnosis, psychological evaluation and management. *Medicine (Baltimore)*. 1996;75:64–76.
 15. Thuyen U, Lanz K, Holterhus PM, Hiort O. Epidemiology and initial management of ambiguous genitalia at birth in Germany. *Horm Res*. 2006;66:195–203.
 16. Erdoğan S, Kara C, Uçaktürk A, Aydın M. Etiological classification and clinical assessment of children and adolescents with disorders of sex development. *J Clin Res Pediatr Endocrinol*. 2011;3:77–83.
 17. Xavier NA, McGill JB. Hyperandrogenism and intersex controversies in women's Olympics. *J Clin Endocrinol Metab*. 2012;97:3902–3907.
 18. Vague J. *Explorations clinique des syndromes testiculaires in "Notions d'Endocrinologie."* Paris: Jean Vague (Flammarion); 1965:300.



THE
ENDOCRINE
SOCIETY®



Submit your best science for presentation in an oral or poster session
at ENDO 2013, June 15 - 18, 2013, San Francisco, California
Abstract Submission Deadline: January 30, 2013 12:00PM (noon) ET

www.endo-society.org/endo2013