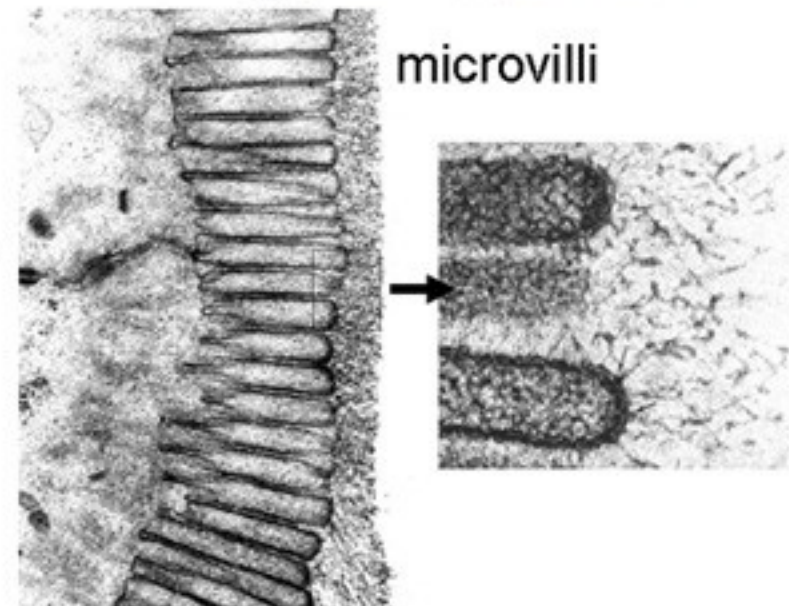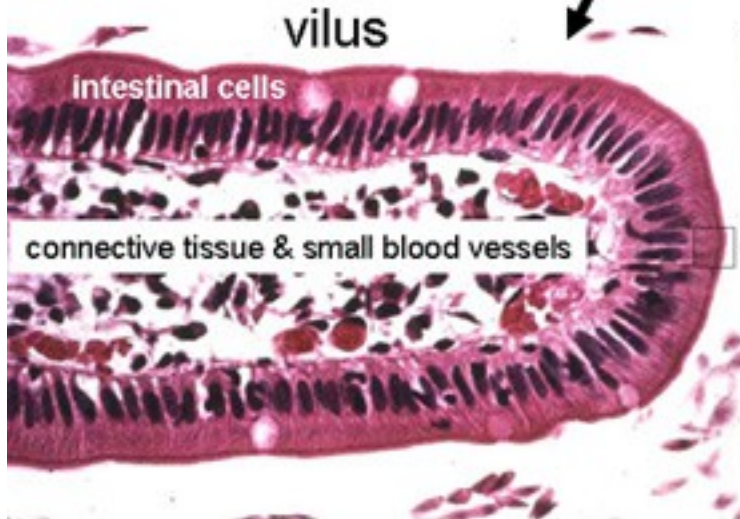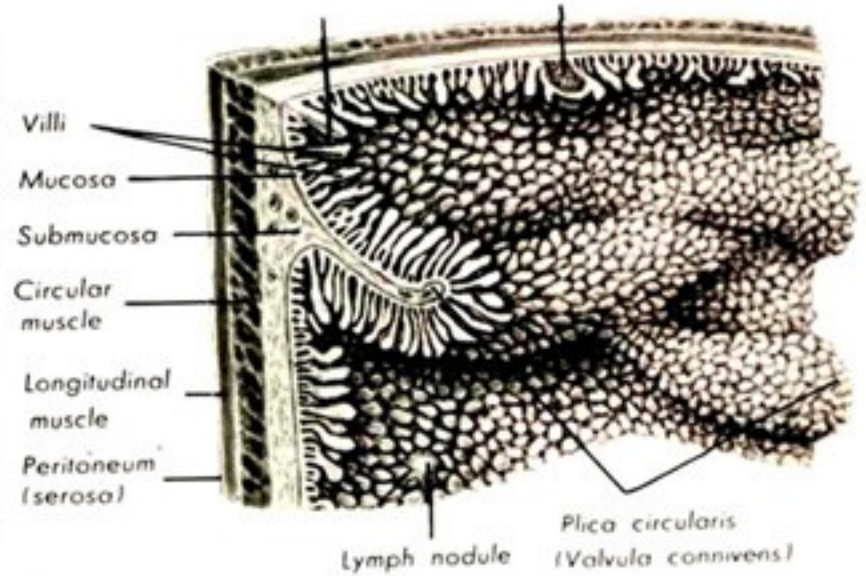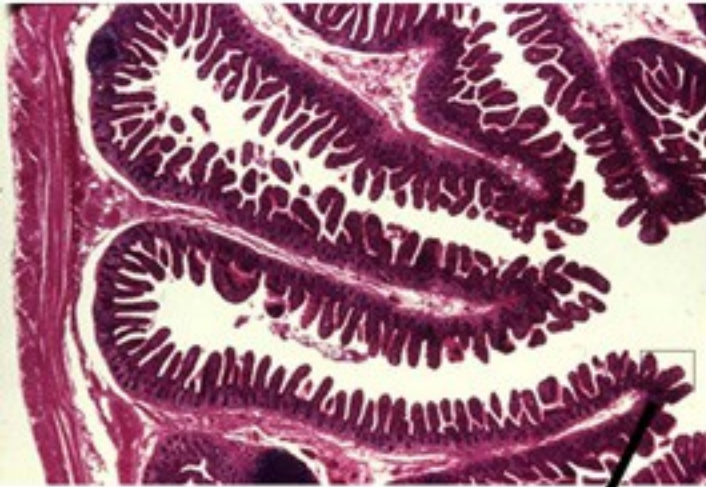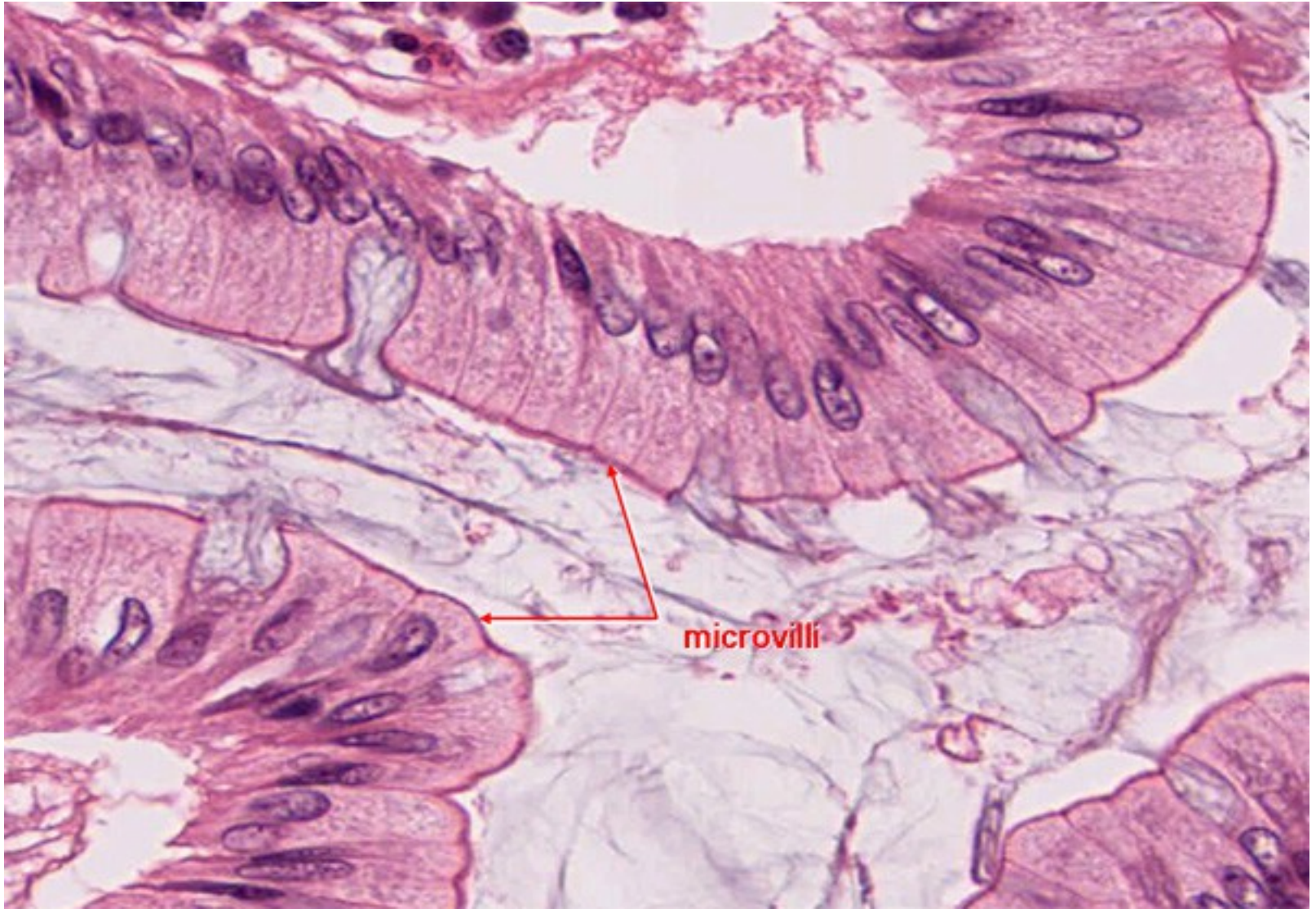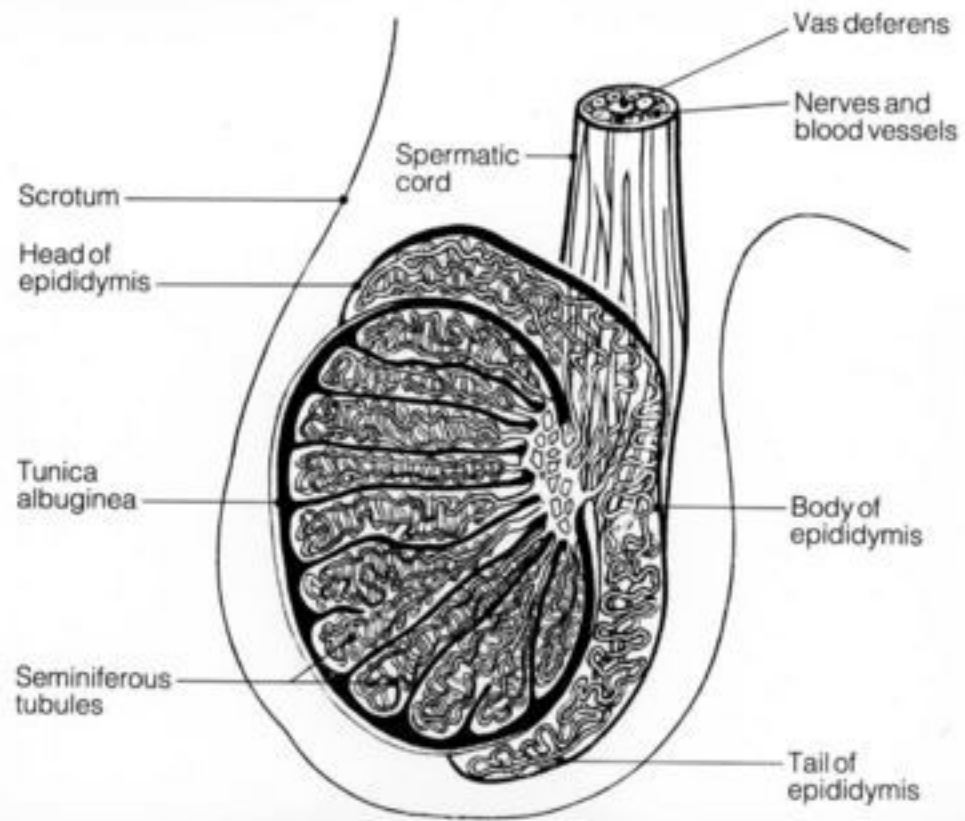
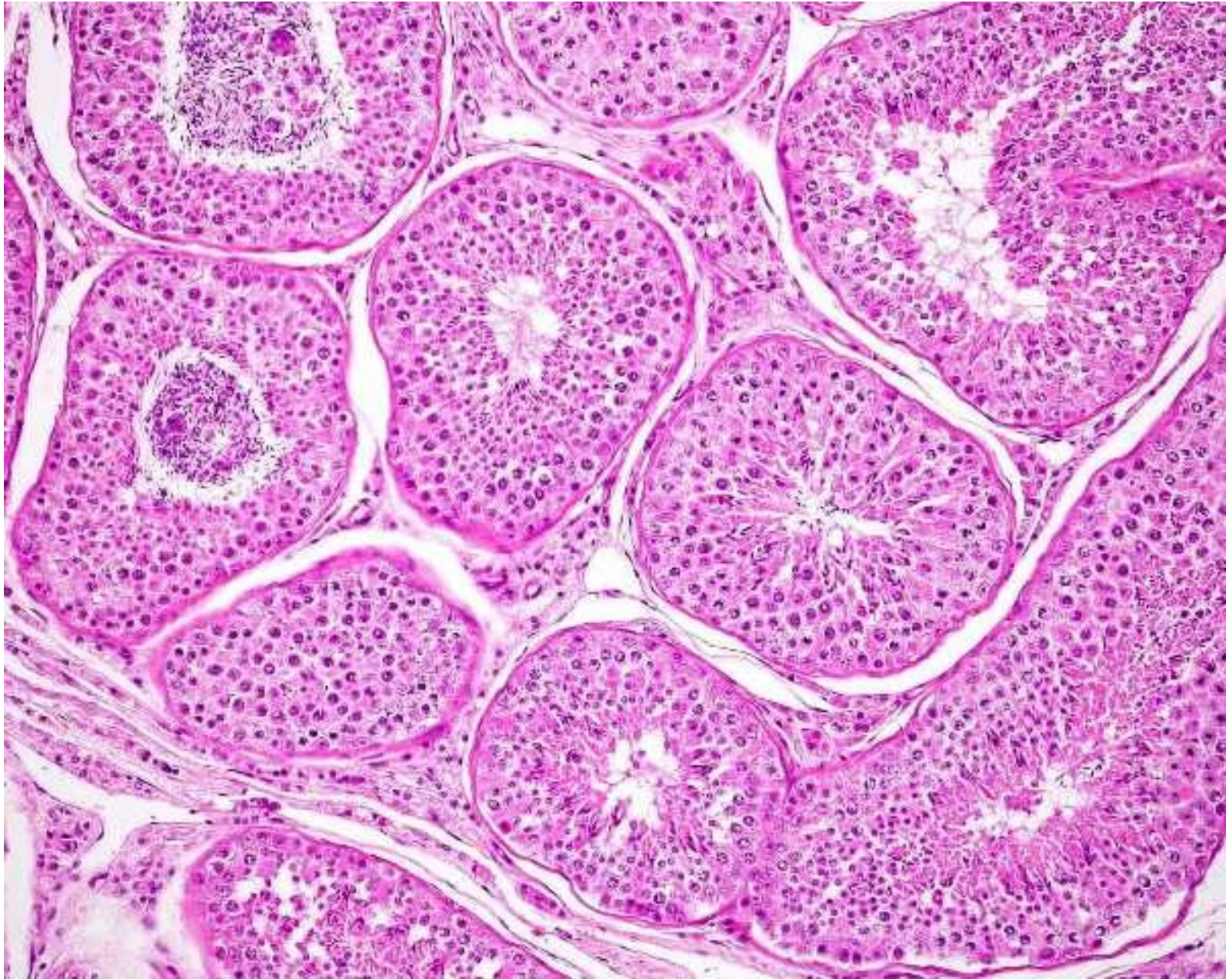
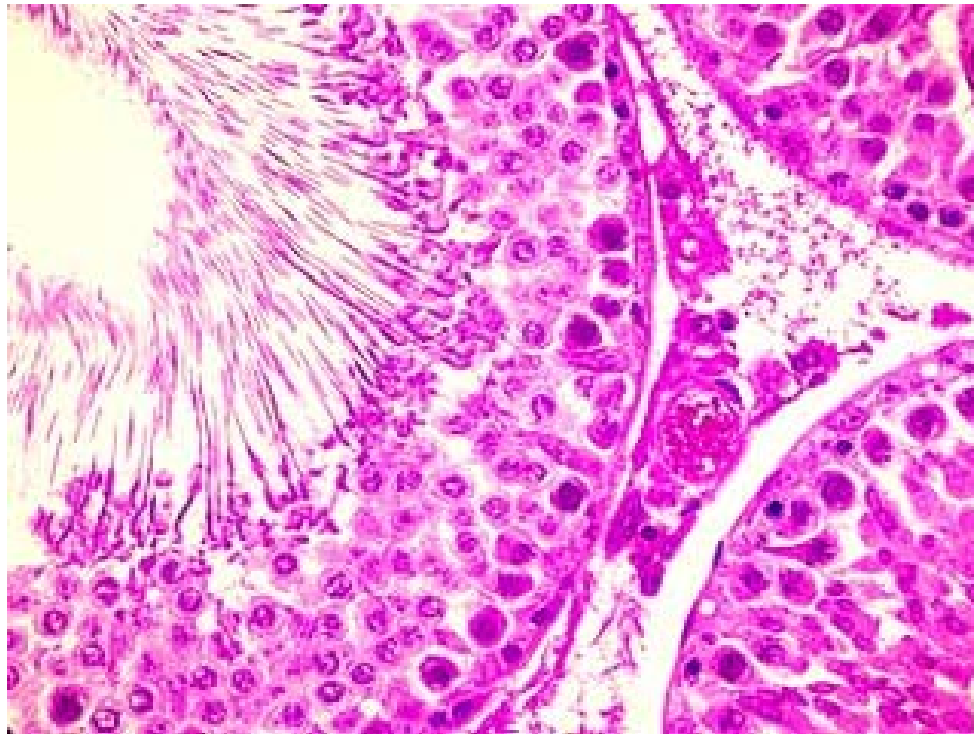
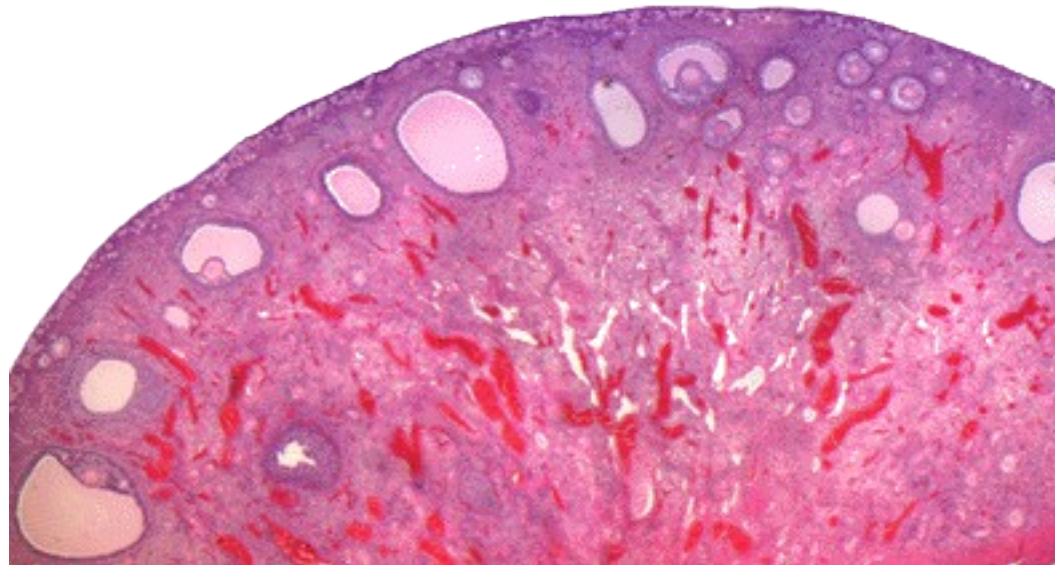



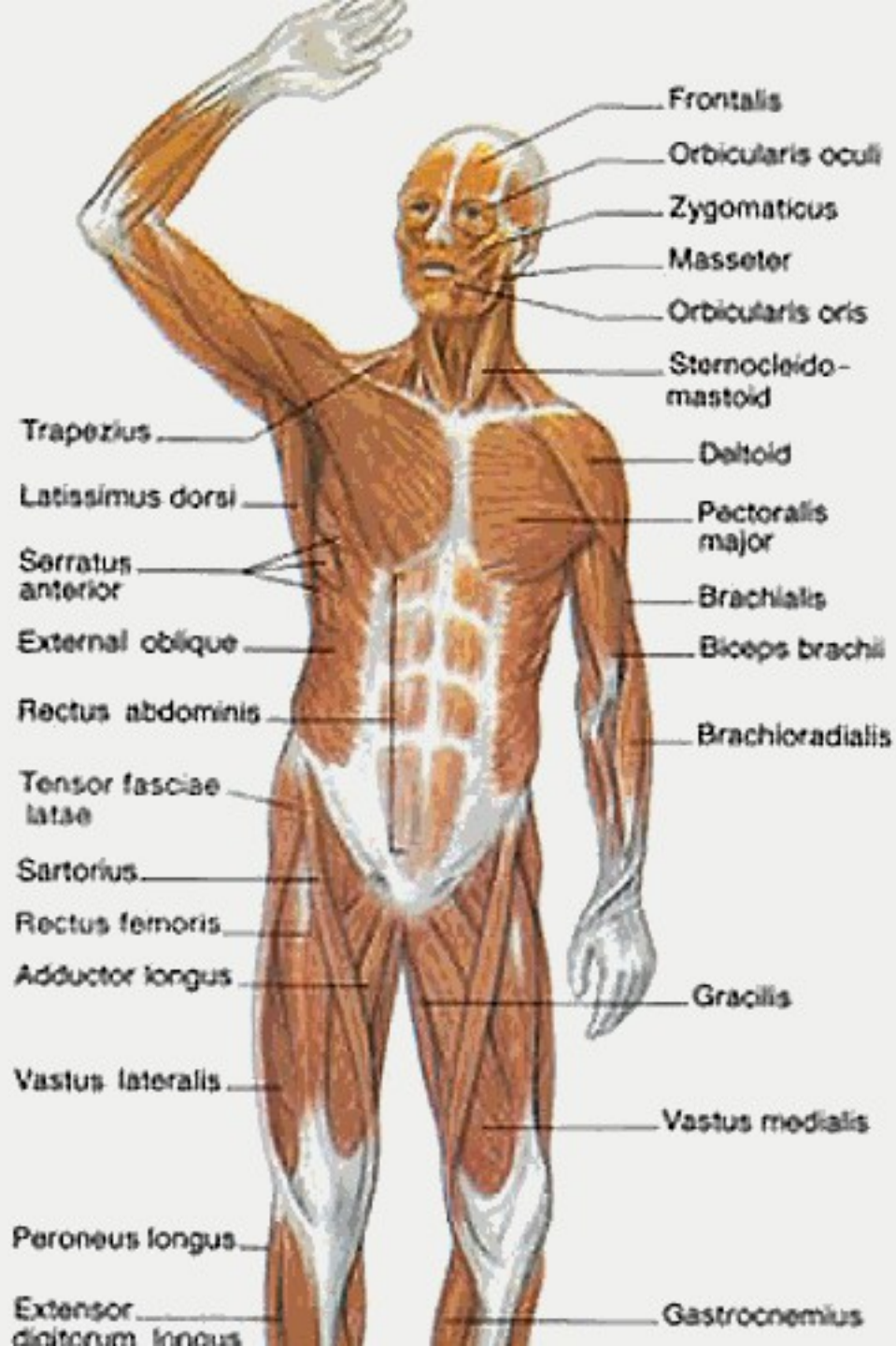Cross Section of Testicle

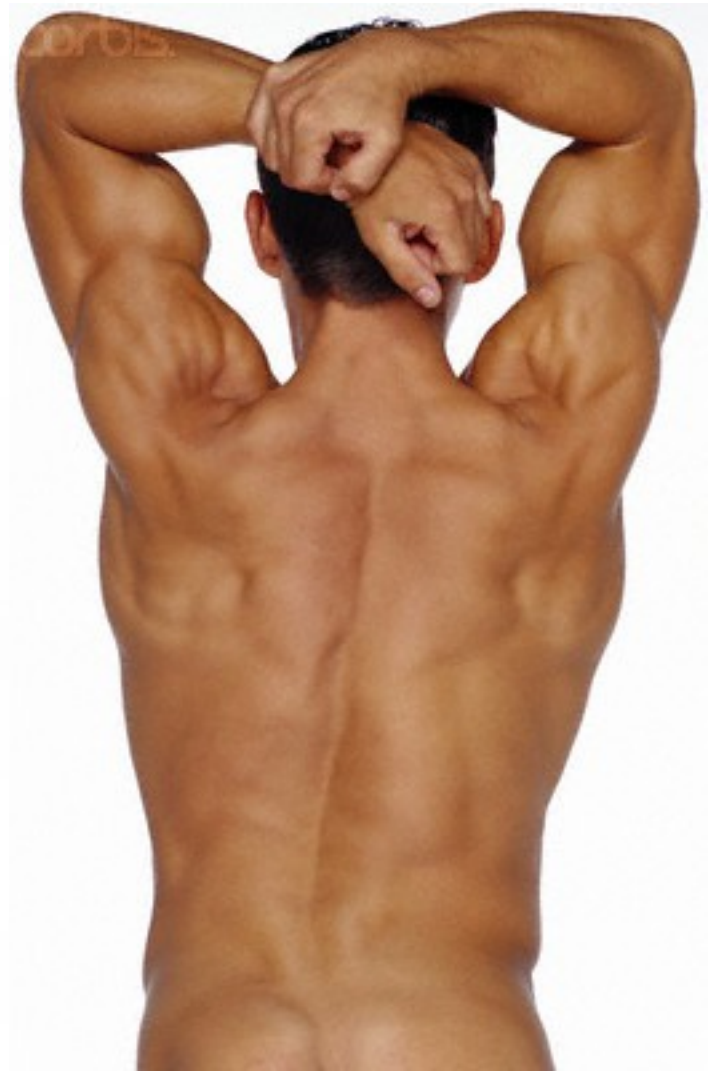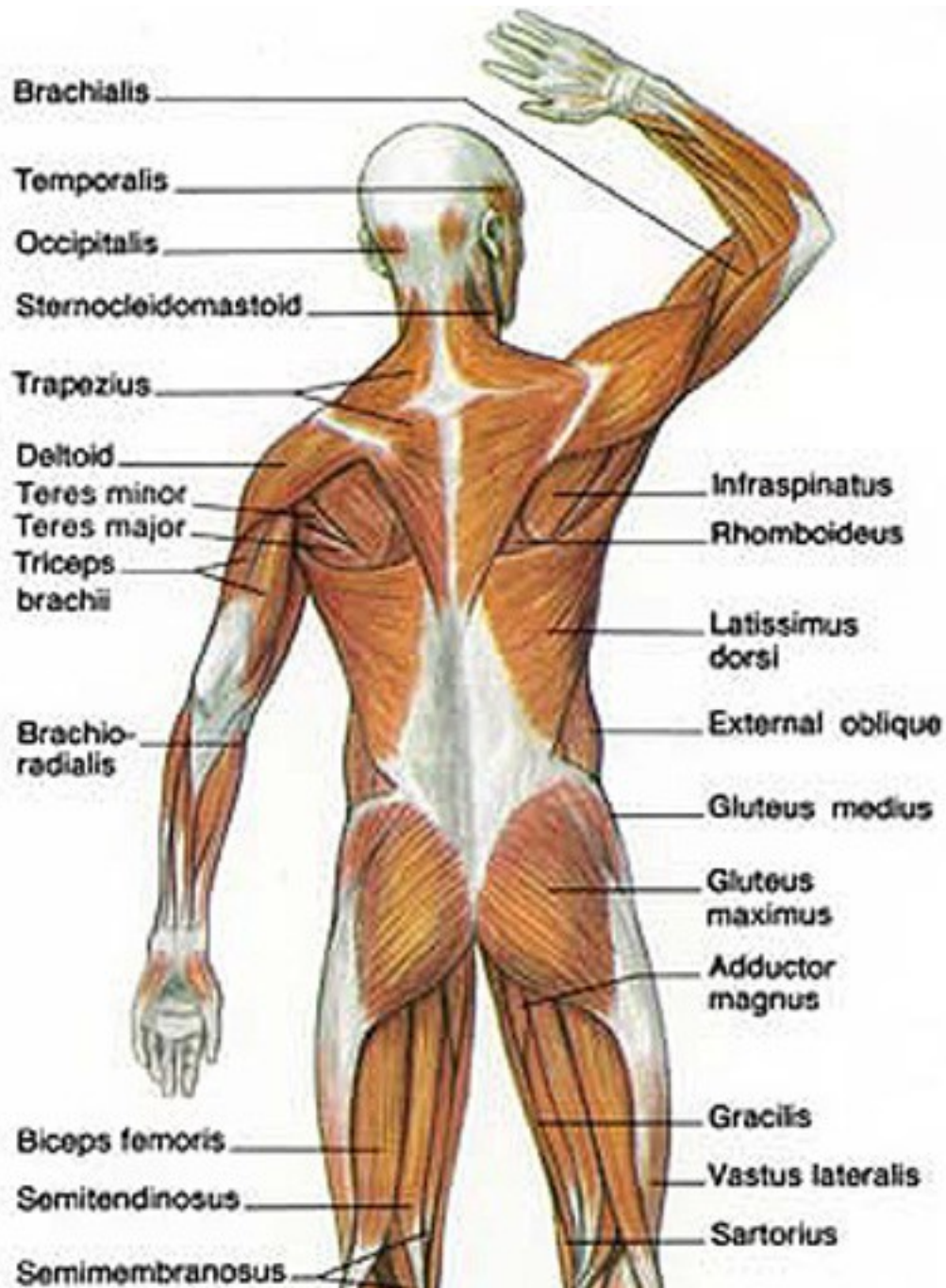


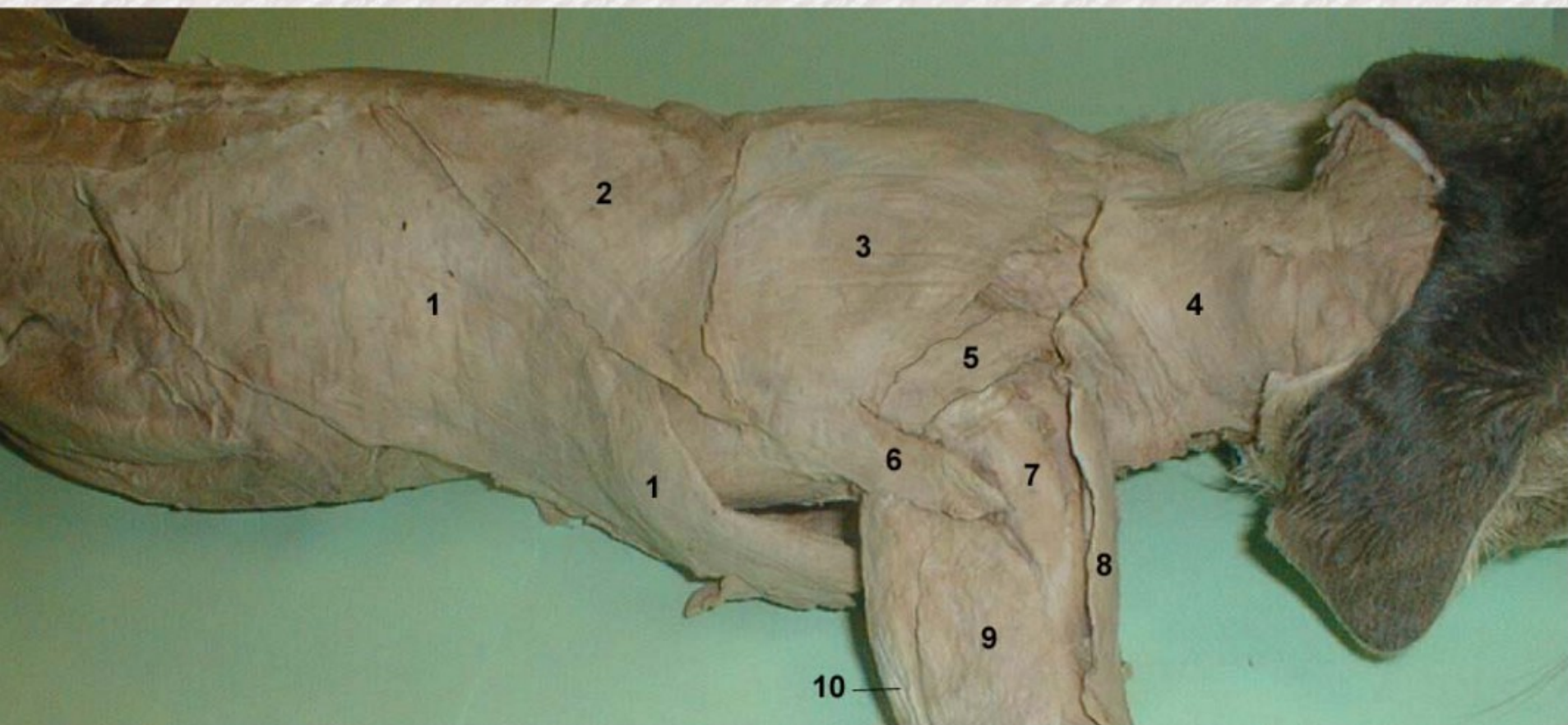


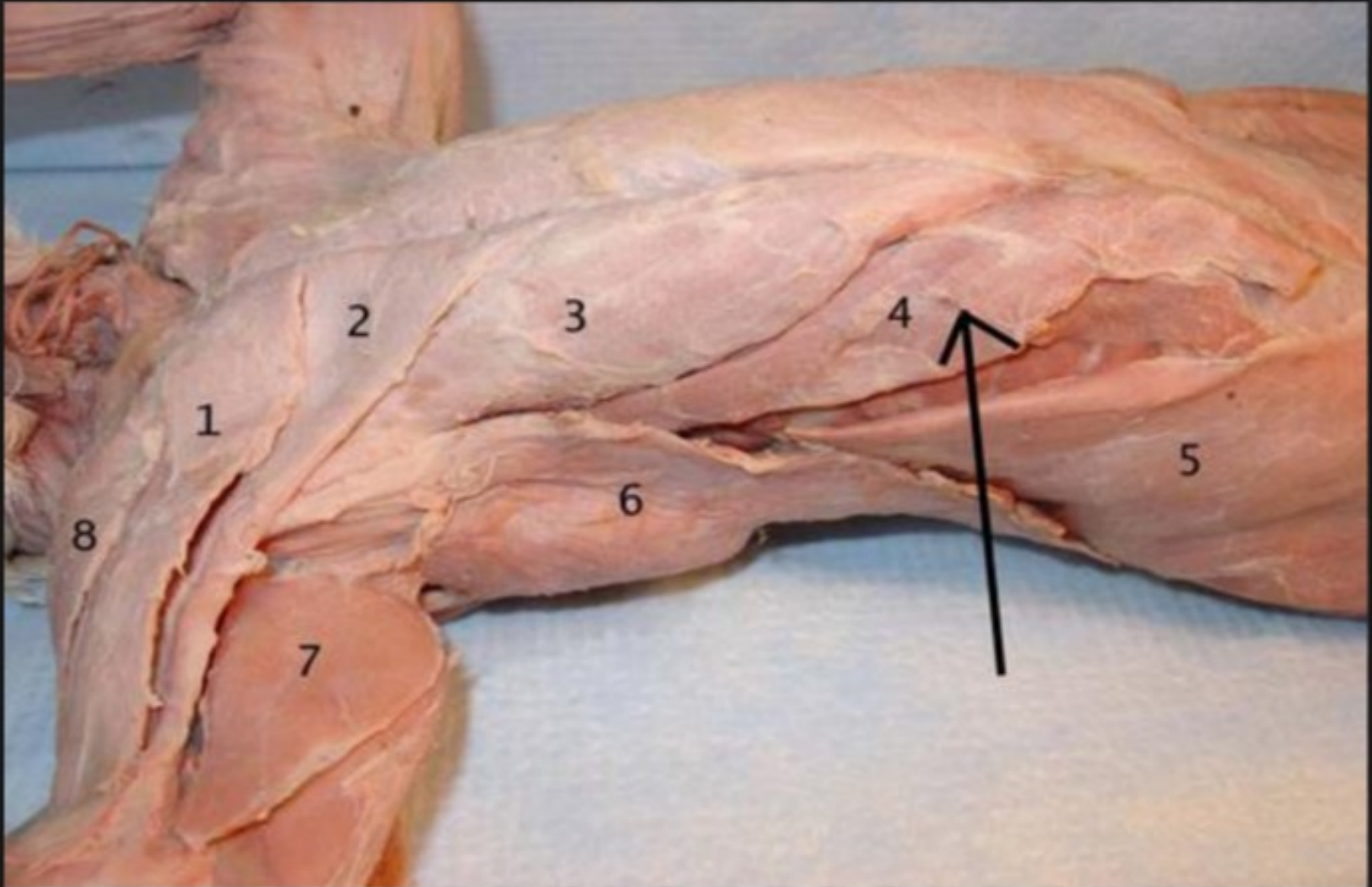


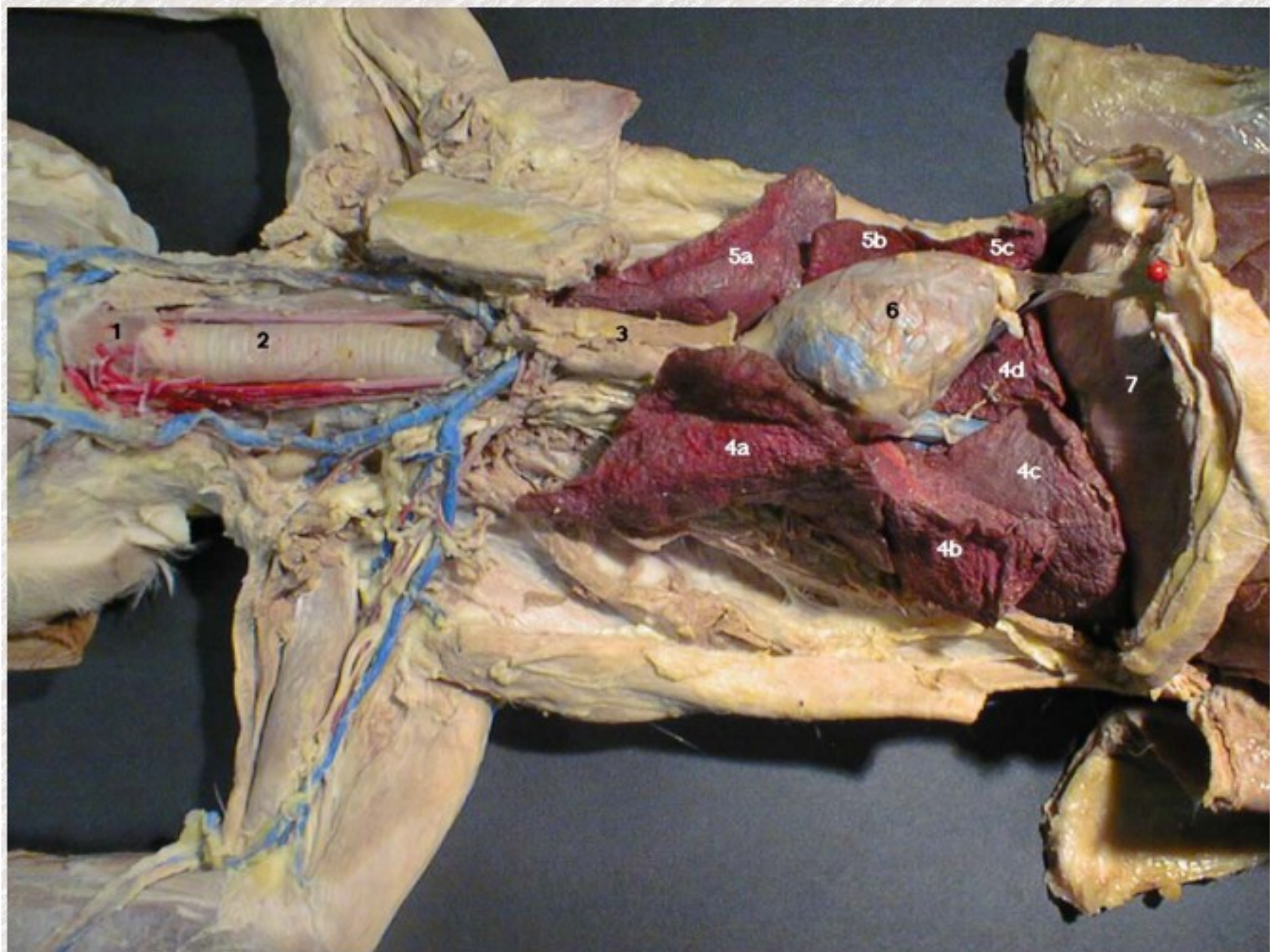


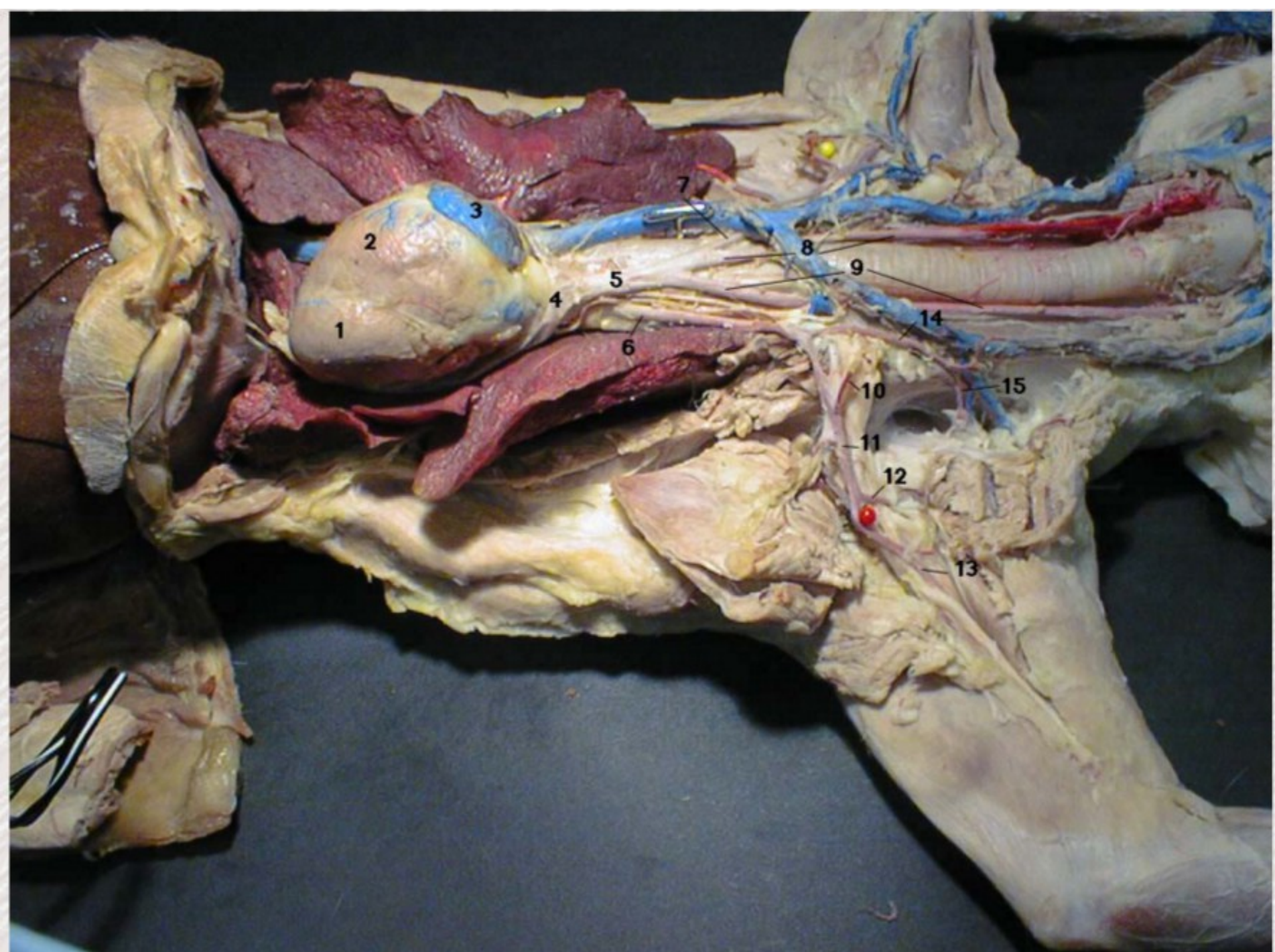




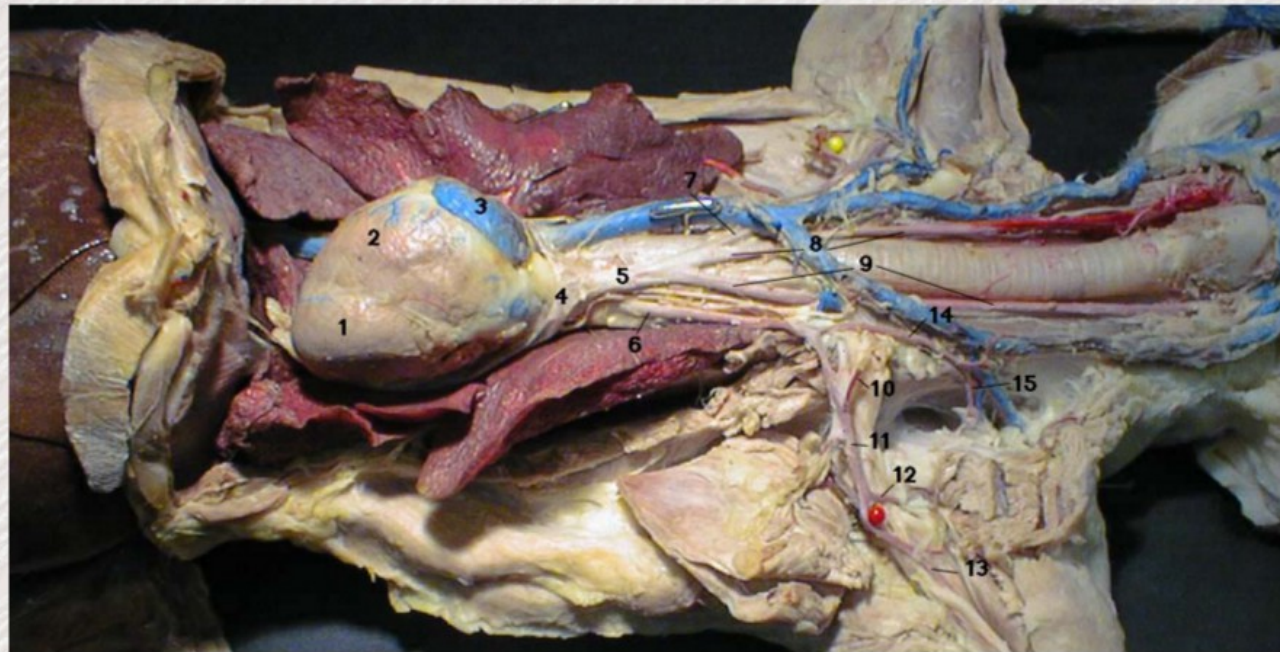


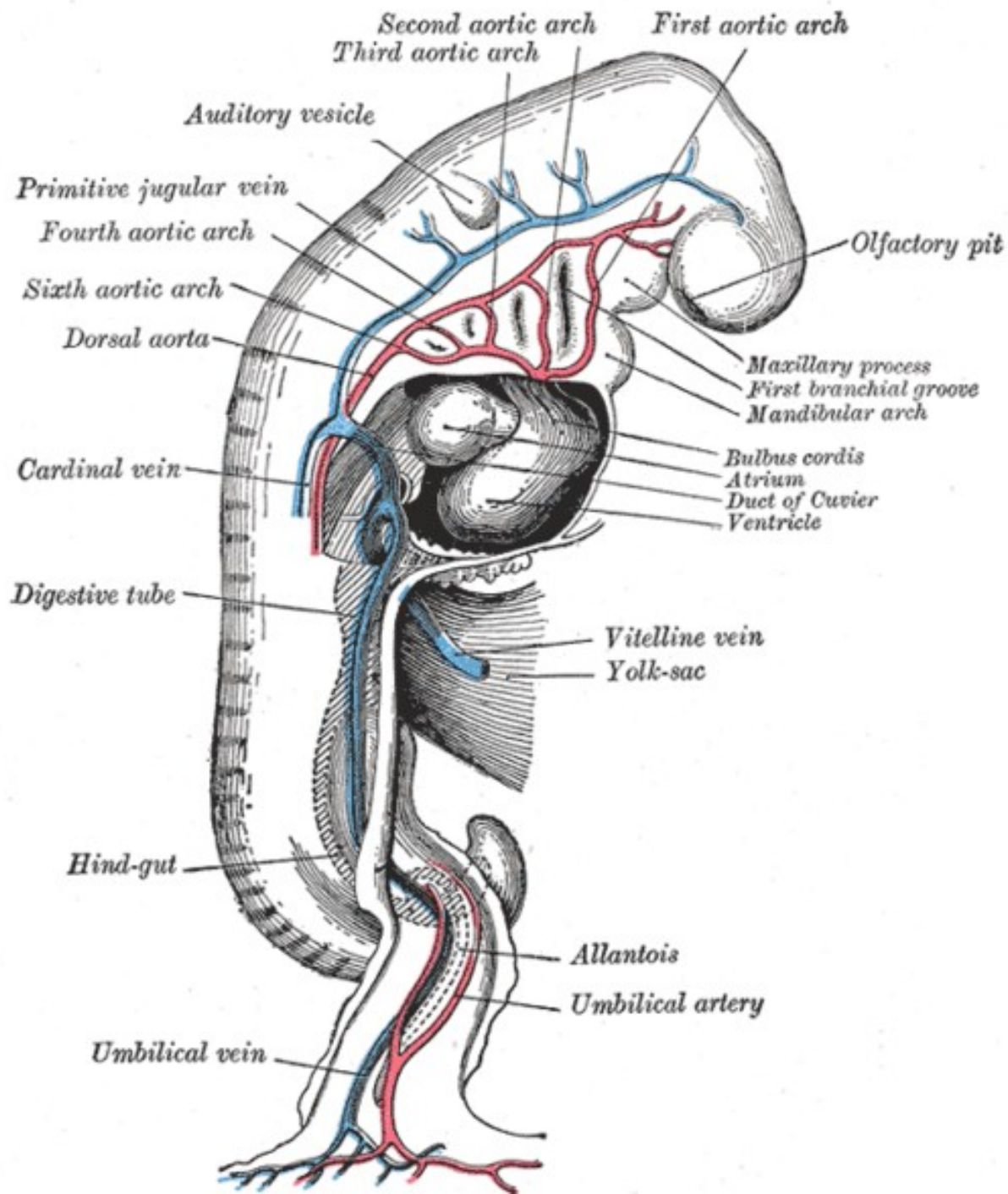


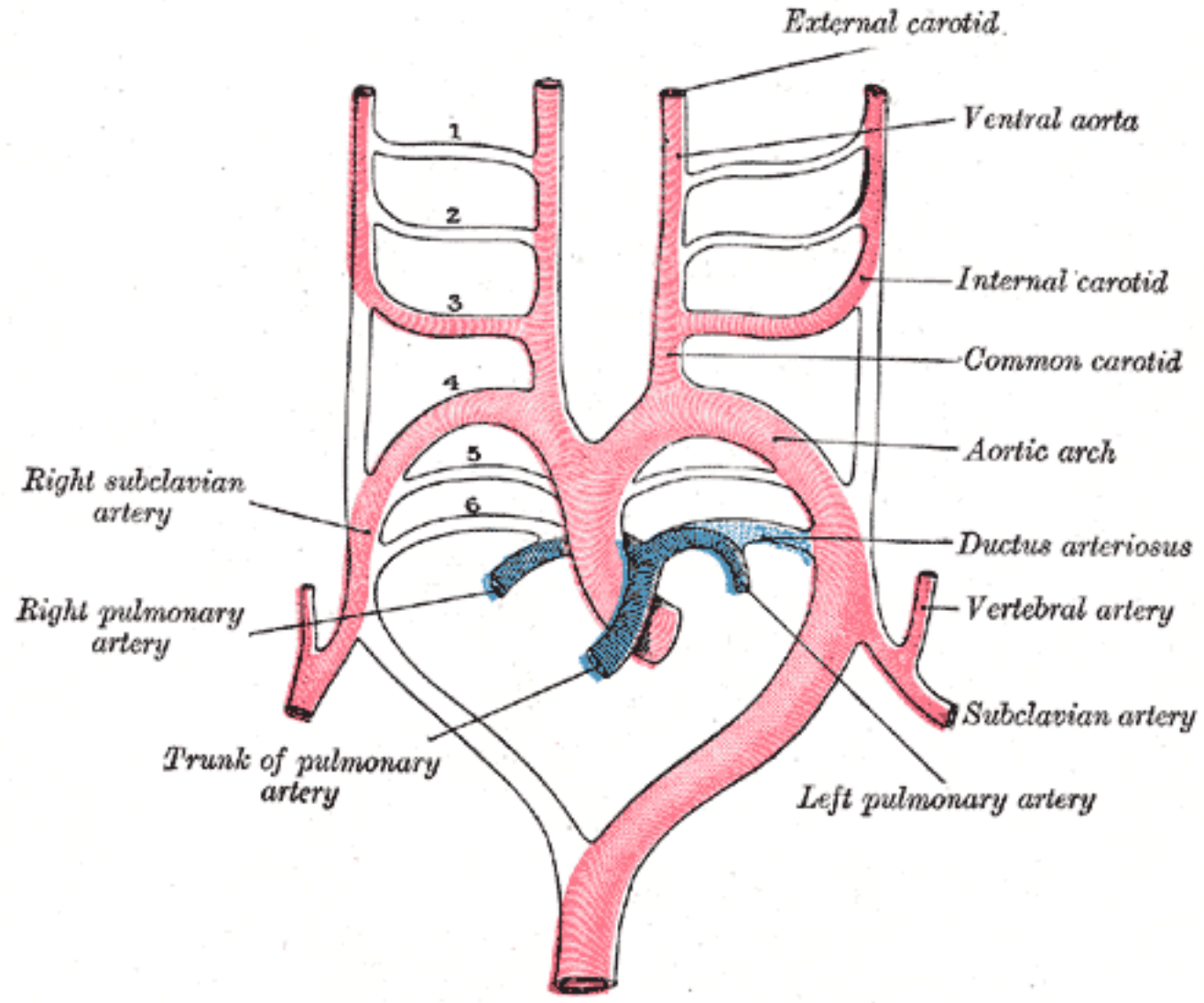



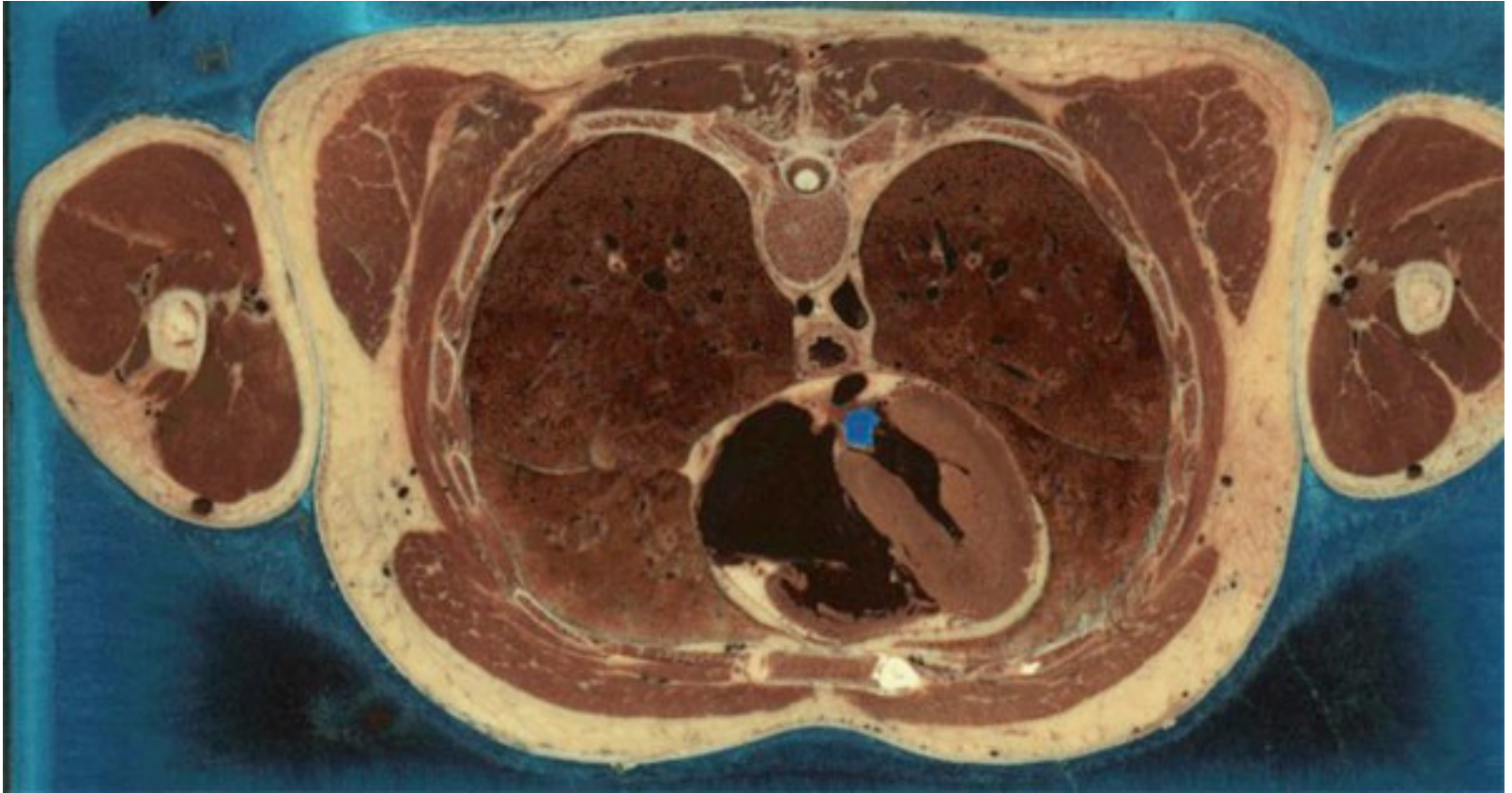
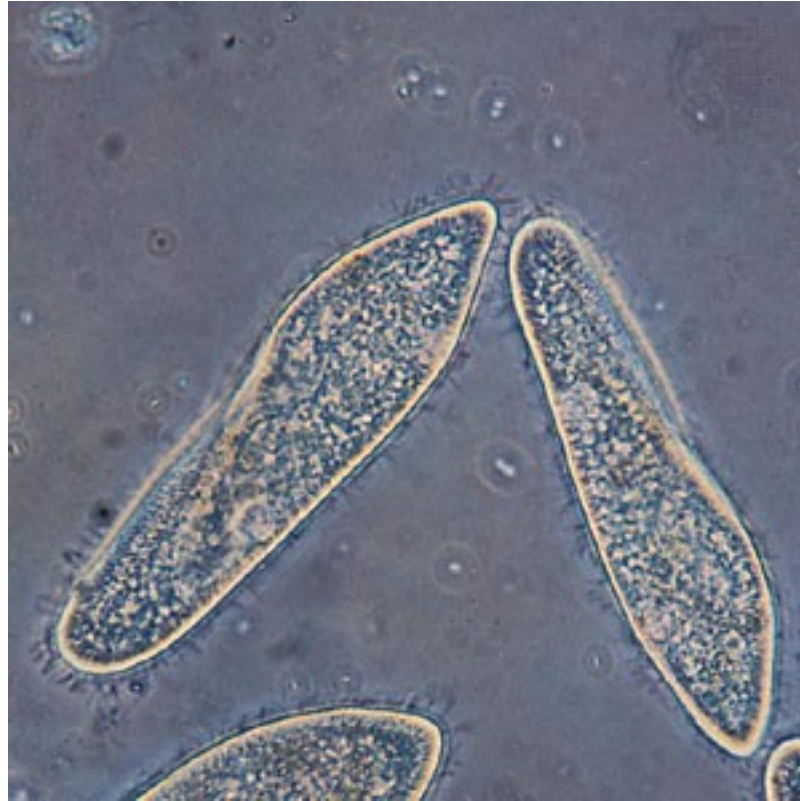1. Left Ventricle of Heart
2. Right Ventricle of Heart
3. Right Auricle of Heart
4. Aortic Arch
5. Brachiocephalic Artery
6. Left Subclavian Artery
7. Right Subclavian Artery
8. Right Common Carotid Artery
9. Left Common Carotid Artery
10. Left Internal Mammary Artery
11. Left Axillary Artery
12. Left Subscapular Artery
13. Left Brachial Artery
14. Left Thyrocervical Artery
15. Left Transverse Scapular Artery

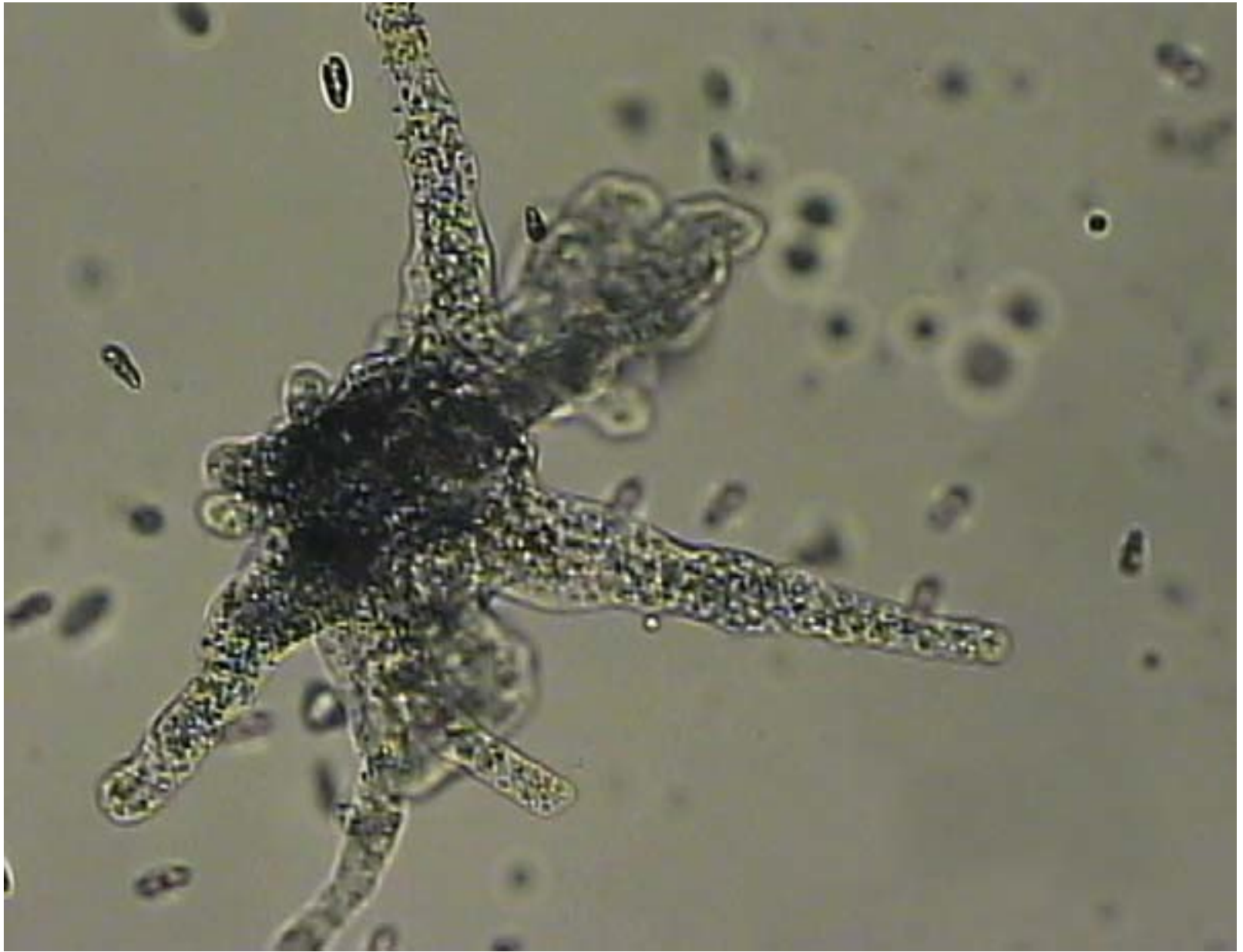


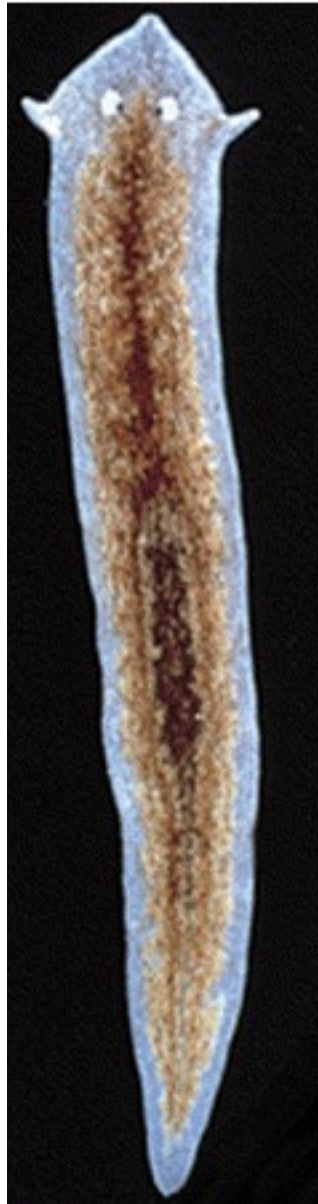


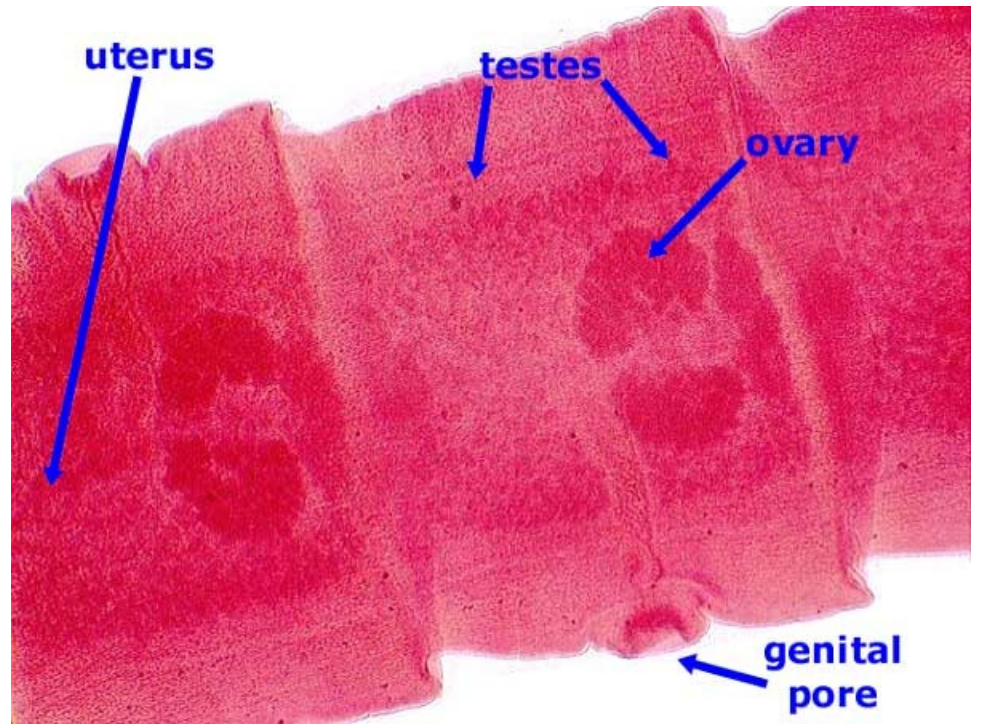


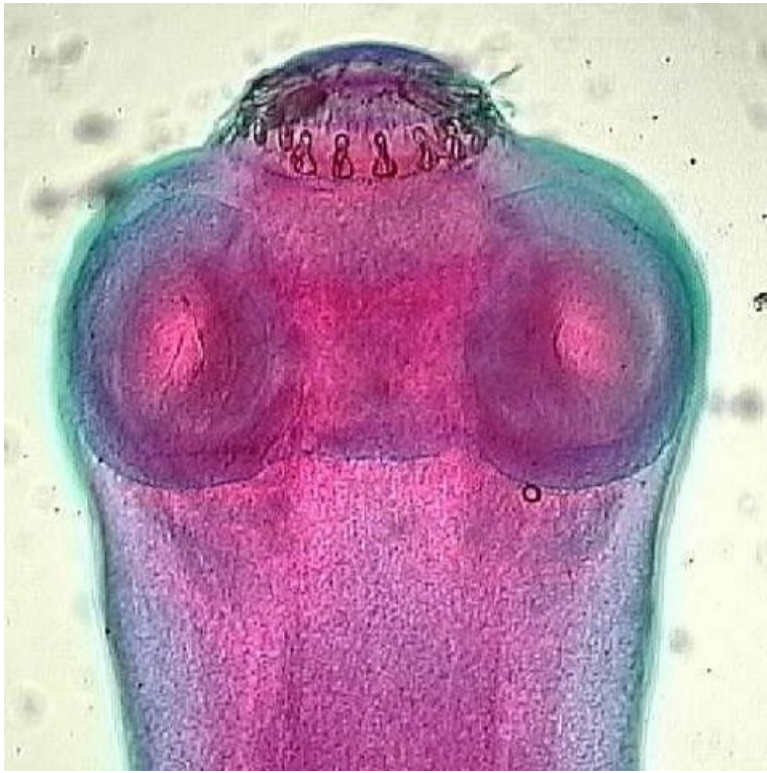

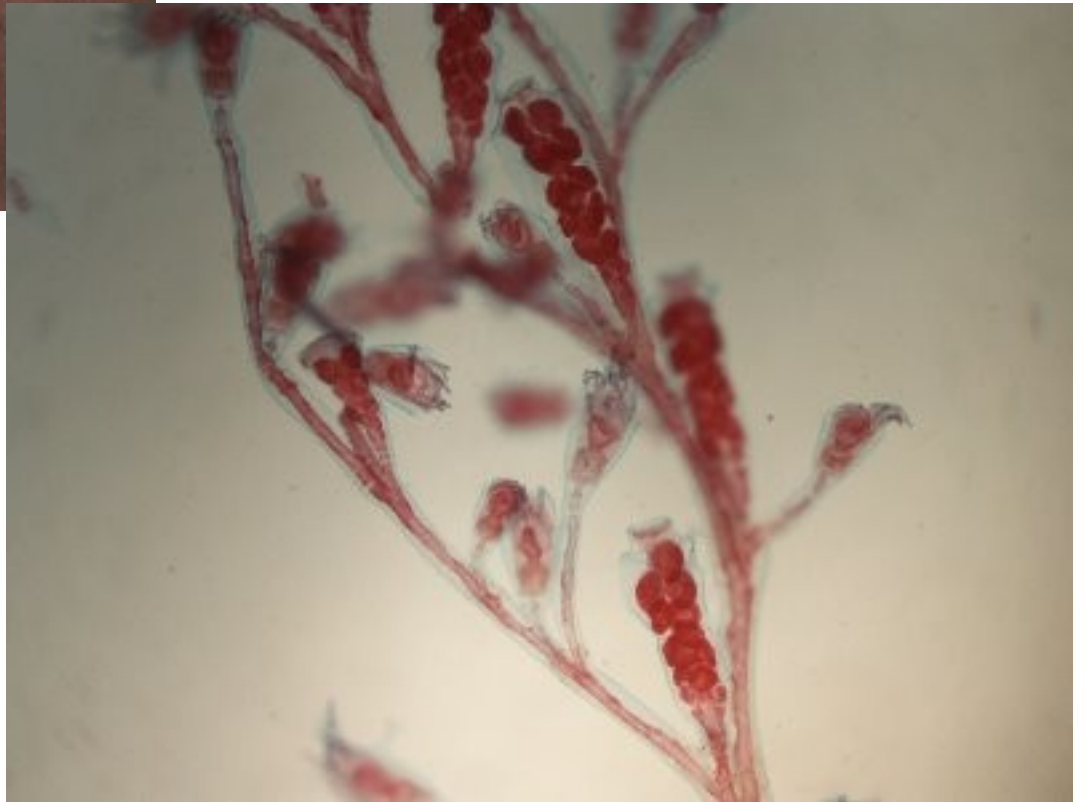
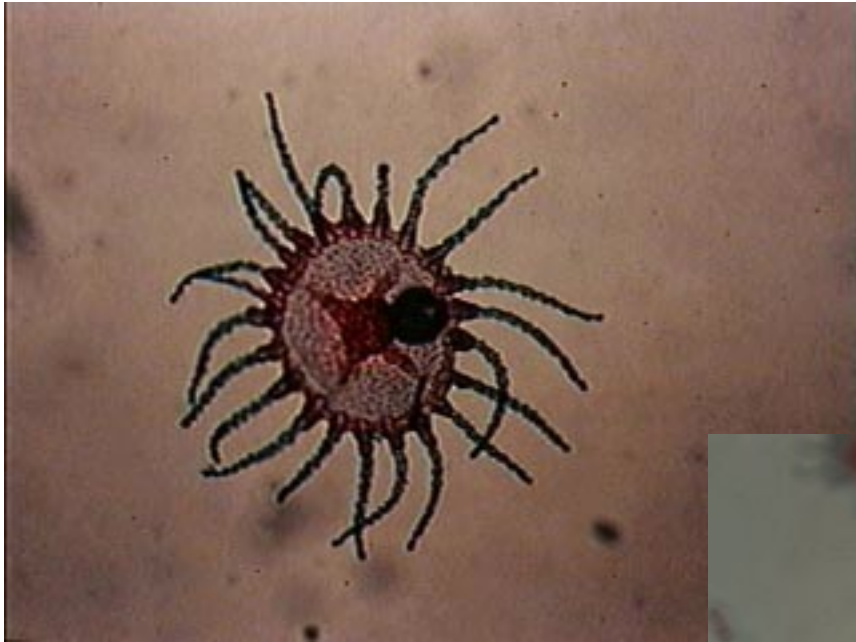






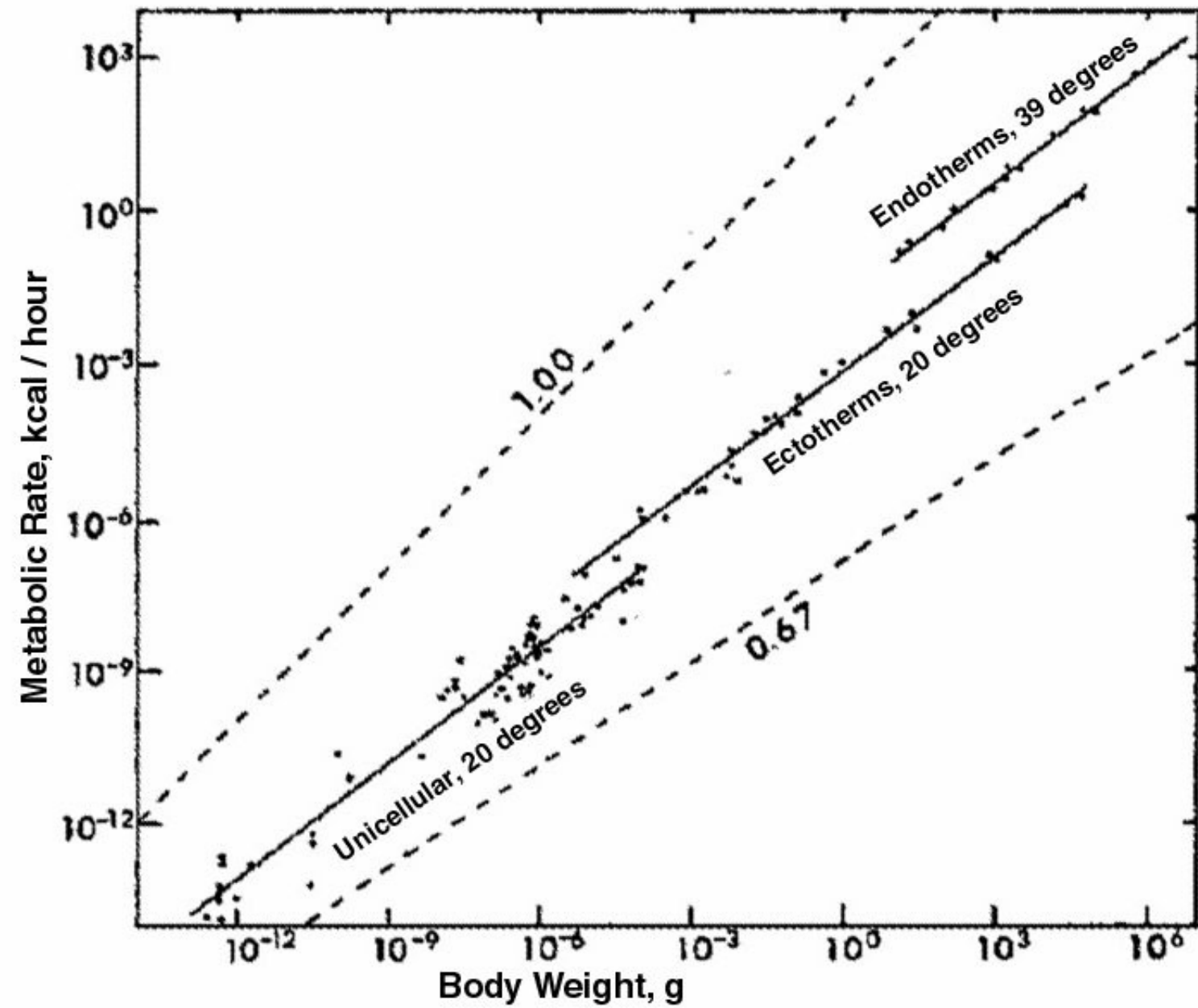
5 mm

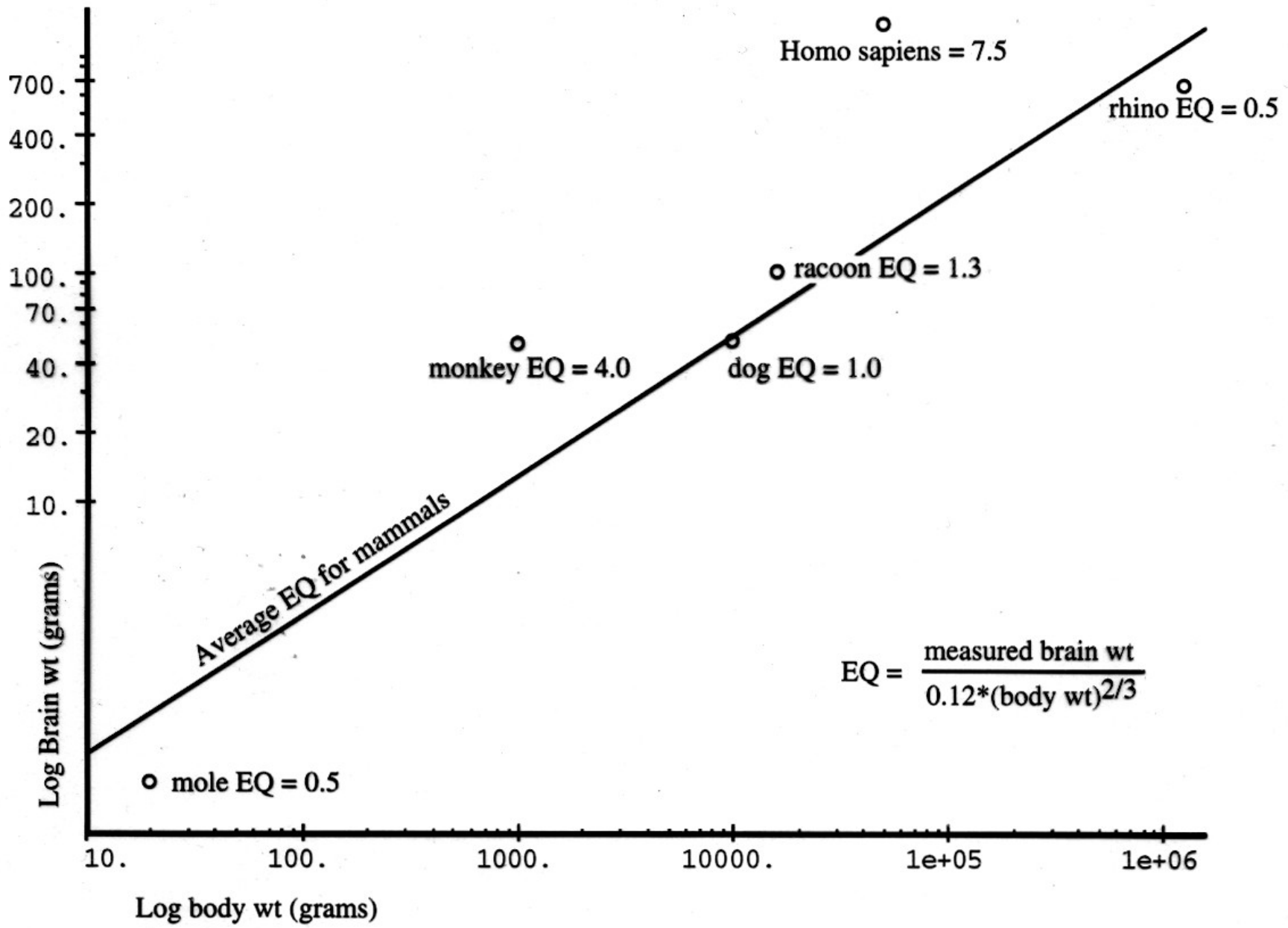


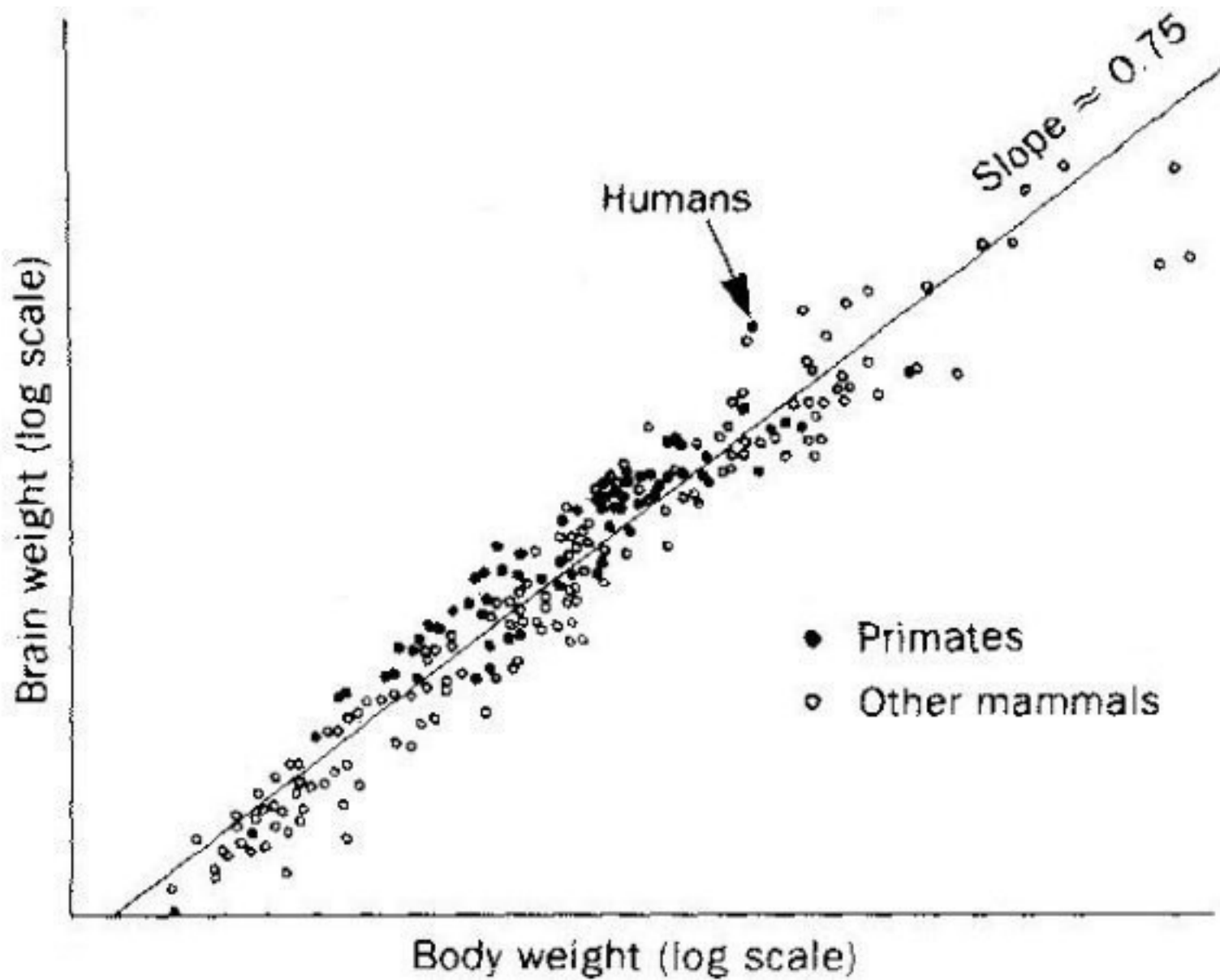


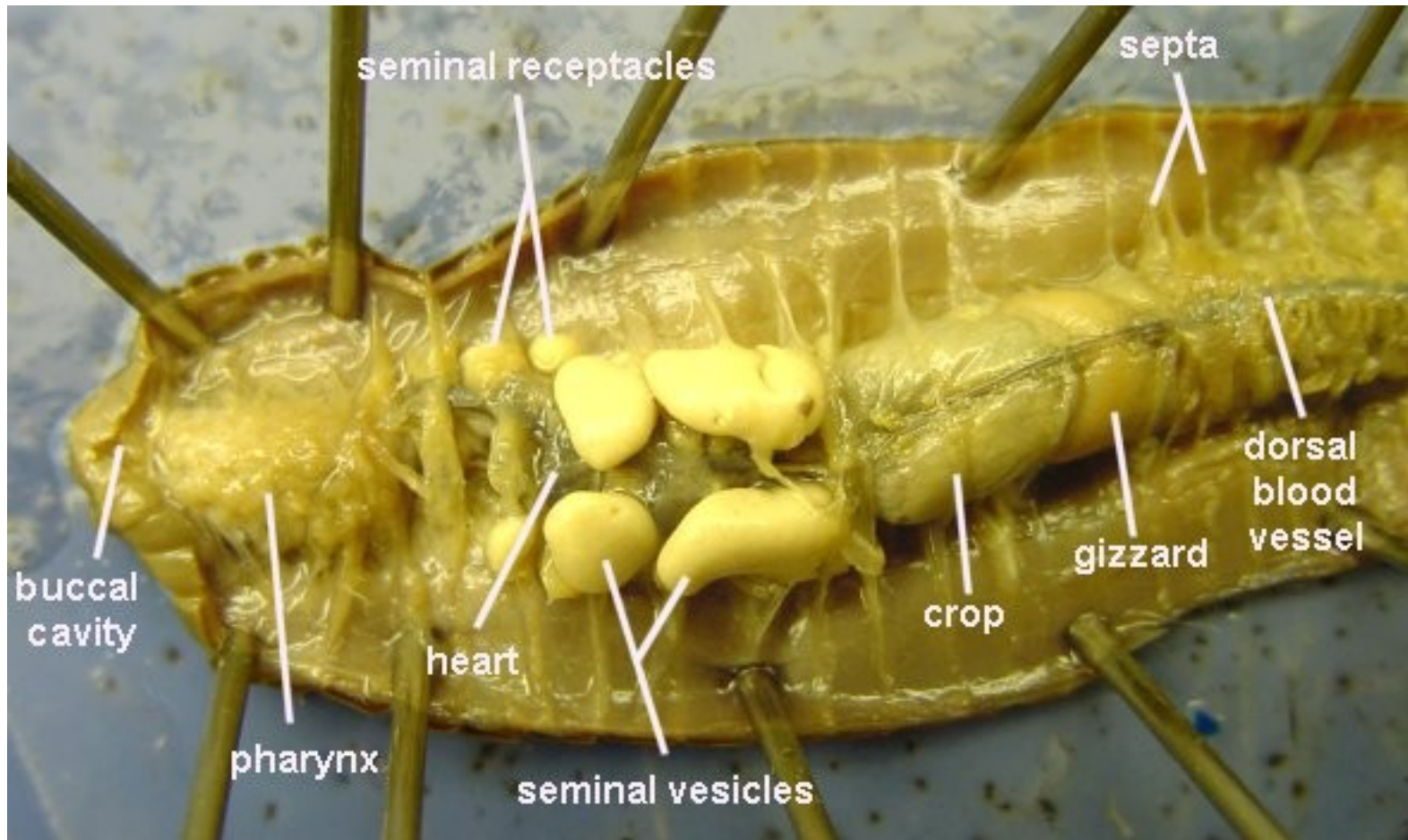




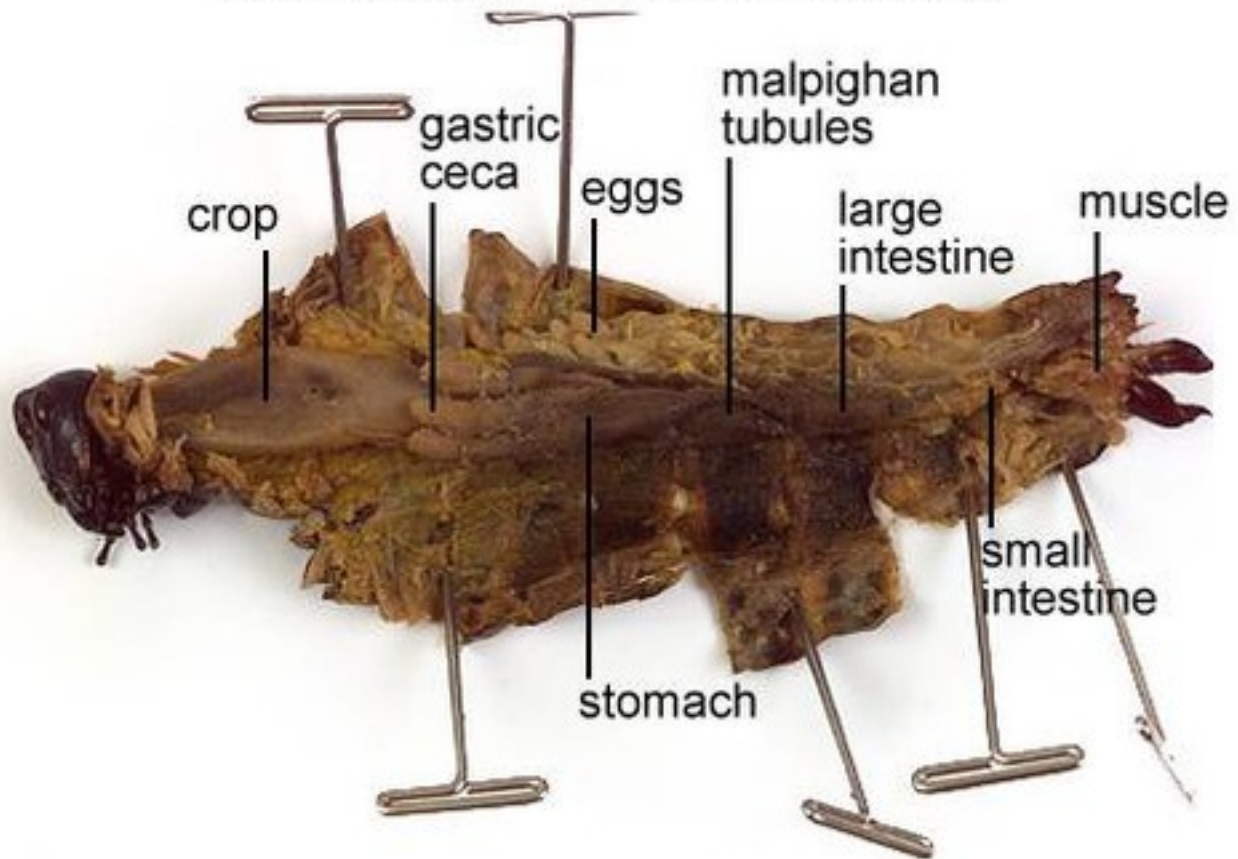


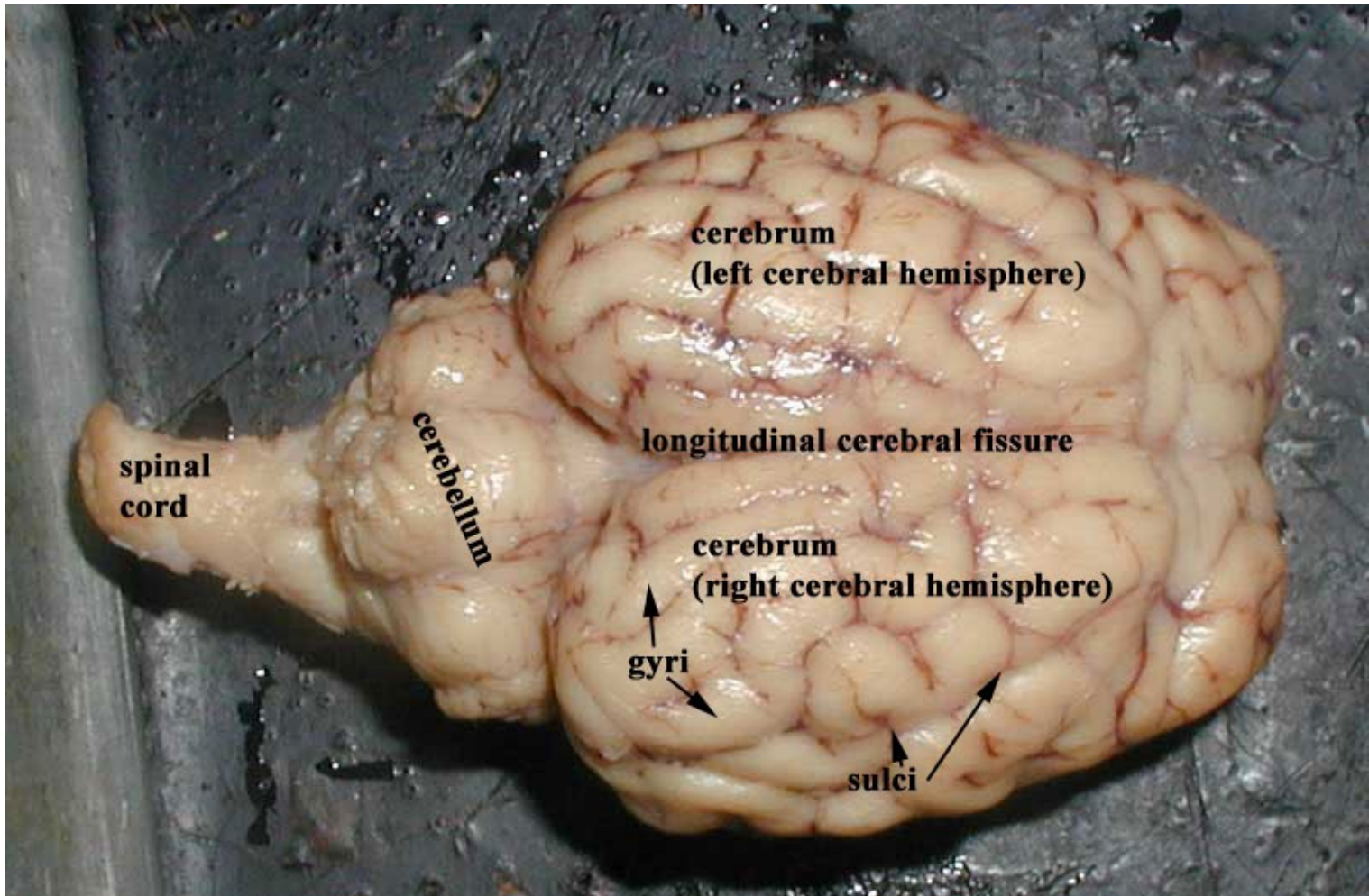


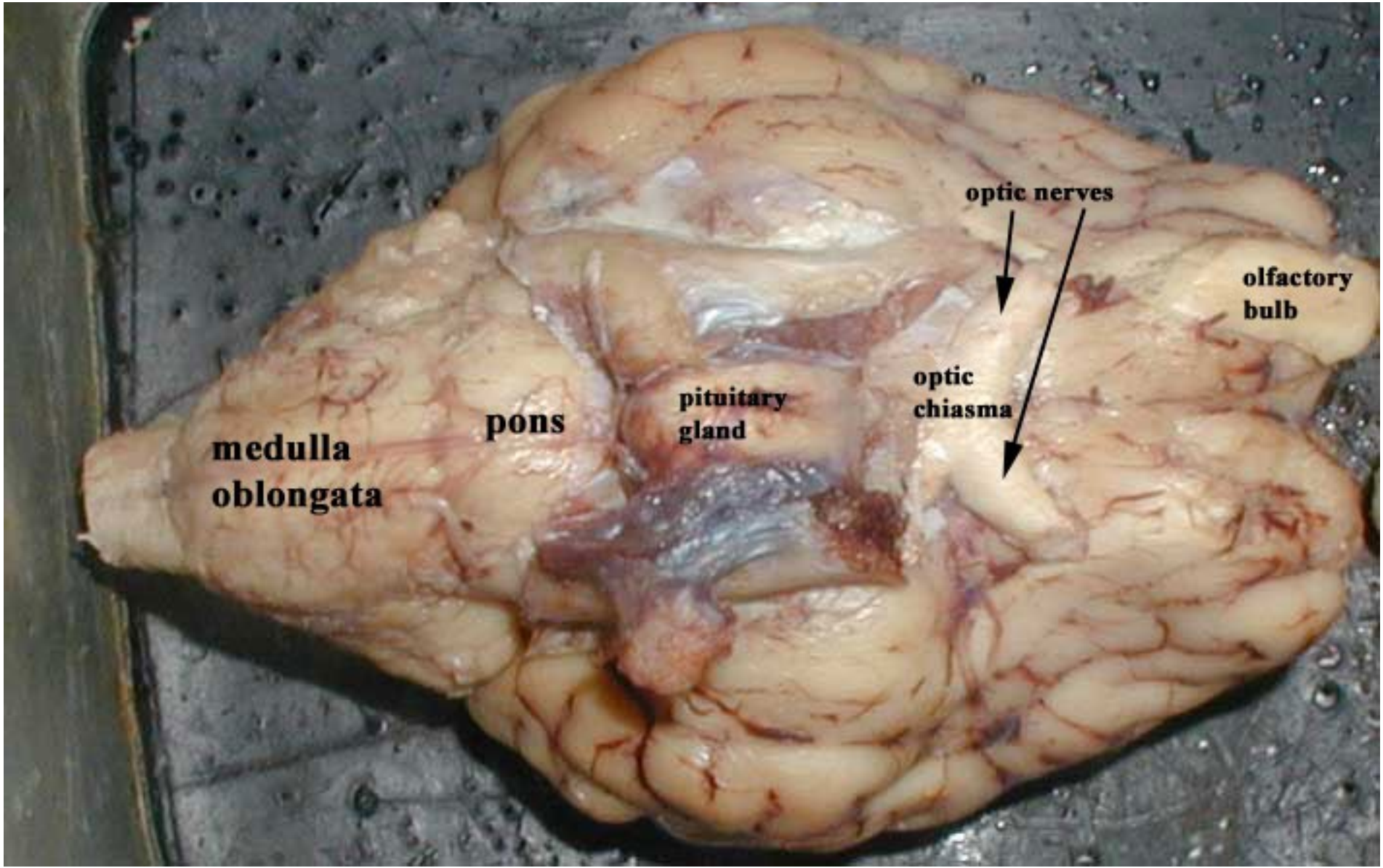




Grasshopper - Internal Features







**medulla
oblongata**

pons

**pituitary
gland**

**optic
chiasma**

optic nerves

**olfactory
bulb**

